

# Lipoma parafaríngeo a causar obstrução da via aérea - case report

## Caso Clínico

### Autores

**Joana Ida Dias**  
Unidade Local de Saúde de Santo António, Porto, Portugal

**Sara Raquel Azevedo**  
Unidade Local de Saúde de Santo António, Porto, Portugal

**Ana Isabel Pereira**  
Unidade Local de Saúde de Santo António, Porto, Portugal

**Ana Pereira Silva**  
Unidade Local de Saúde de Santo António, Porto, Portugal

**Rita Carvalho**  
Unidade Local de Saúde de Santo António, Porto, Portugal

**Luís Meireles**  
Unidade Local de Saúde de Santo António, Porto, Portugal

**Telma Feliciano**  
Unidade Local de Saúde de Santo António, Porto, Portugal

**Correspondência:**  
Joana Ida Dias  
joanaidasousadias@gmail.com

Artigo recebido a 23 de Setembro de 2024.  
Aceite para publicação a 2 de Janeiro de 2025.

### Resumo

Os lipomas parafaríngeos são tumores benignos raros, representando menos de 0,5% de todas as neoplasias do espaço parafaríngeo. A sua proximidade com estruturas anatómicas críticas exige uma avaliação diagnóstica cuidadosa e correção cirúrgica apropriadas. Relatamos o caso clínico de uma mulher de 69 anos que se apresentou no nosso hospital com disfagia, roncopatia e dispneia progressivas. O exame objetivo e os estudos de imagem revelaram um lipoma parafaríngeo, que foi removido com sucesso através de cirurgia. O diagnóstico foi confirmado por exame anatomopatológico, e a doente recuperou sem complicações ou recorrência dos sintomas. Este caso realça a importância de um diagnóstico precoce e de uma abordagem cirúrgica adequada para o tratamento de lipomas nesta localização pouco comum. Palavras-chave: obstrução das vias aéreas superiores; espaço parafaríngeo; tumores espaço parafaríngeo; neoplasias da cabeça e pescoço, lipoma

### Introduction

Lipomas are benign tumors composed of mature adipose tissue, commonly found in various parts of the body but rarely in the parapharyngeal space, accounting for less than 0.5% of tumors in this area. Although benign, differential diagnosis with metastatic lesions, branchial cysts or neurogenic tumors is mandatory.<sup>1</sup> Due to their location and insidious growth, they can cause compressive symptoms such as dysphagia, dyspnea or a palpable cervical mass, requiring careful investigation and often surgical treatment.<sup>2</sup> Early diagnosis is crucial for effective treatment, as timely surgical intervention can significantly improve the patient's prognosis. Multiple surgical approaches have been reported in the literature, with complete resection being a key factor in reducing recurrence. Depending on the

location of the lesion, surgeons may choose between a transcervical or transoral approach. The transcervical approach is typically performed for retropharyngeal lipomas, as it provides better access to the lateral aspect of the parapharyngeal space. However, there is a higher risk of damage to cranial nerves and carotid vessels with this technique. Transoral approaches have proven safe and effective, with lower postoperative morbidity compared to more invasive open approaches, and may be a suitable option for older patients.<sup>3</sup> All the reported cases of parapharyngeal lipomas emphasize the importance of a detailed diagnostic approach, including clinical examination, imaging studies with computed tomography (CT) or magnetic resonance (MR) imaging, and, in some cases, biopsy for confirmation. While a definitive diagnosis relies on histology, specific imaging characteristics may support a clinical diagnosis. This case highlights the need for a high level of clinical suspicion when evaluating patients with these symptoms, as they can easily be overlooked in the early stages and mistaken for a non-specific neck mass, as we present in this case report.

## Materials and Methods

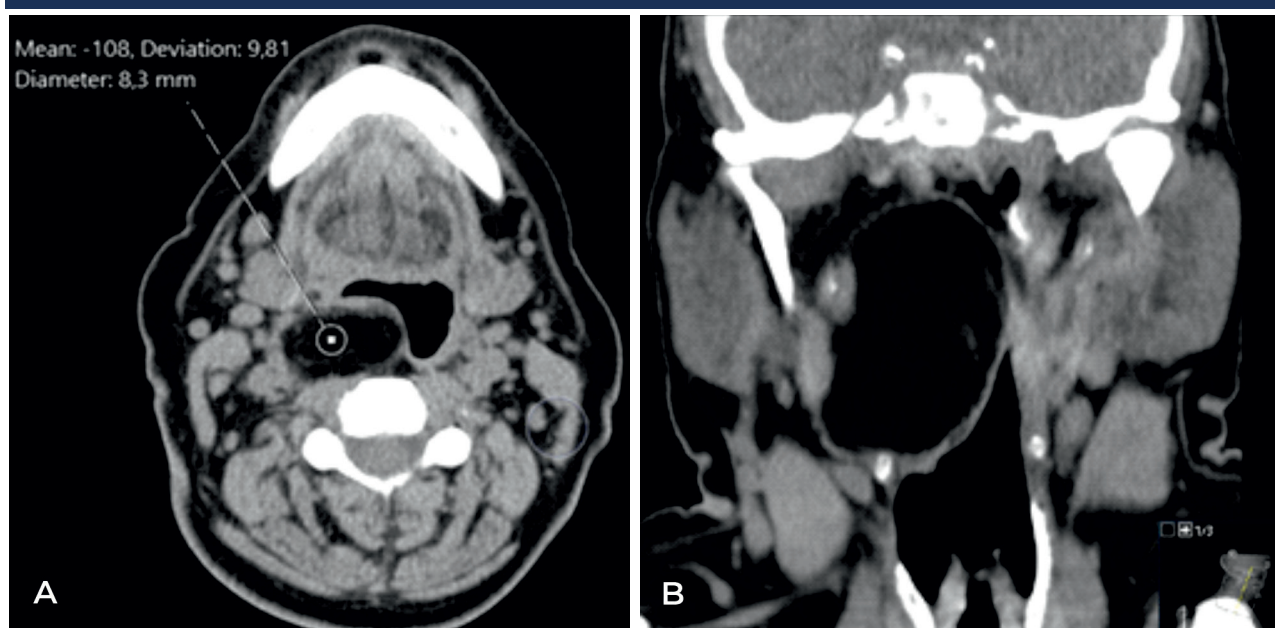
For this review the following keywords were used: "parapharyngeal lipoma," "surgical approach," "head and neck tumors," and "differential diagnosis." The search was conducted in PubMed, Scopus, and Google Scholar. A total of 25 articles were initially identified, of which 10 were selected based on relevance and applicability to the clinical case. The quality of the search was ensured by prioritizing peer-reviewed publications from the last 10 years.

## Clinical Case

We report a clinical case of a 69-year-old woman presenting with a six-month history of progressive dysphagia, snoring and shortness of breath for the last year. Clinical examination revealed a soft bulge over the right lateral wall of the oropharynx, displacing the tonsil medially and reaching the nasopharynx superiorly. Inferiorly the lesion reached the epiglottis, significantly narrowing and lateralizing the airway. A CT scan of the neck - as shown in figure 1 - revealed a large well-circumscribed, hypodense mass measuring 8,3 cm in the right parapharyngeal and retropharyngeal

**Figure 1**

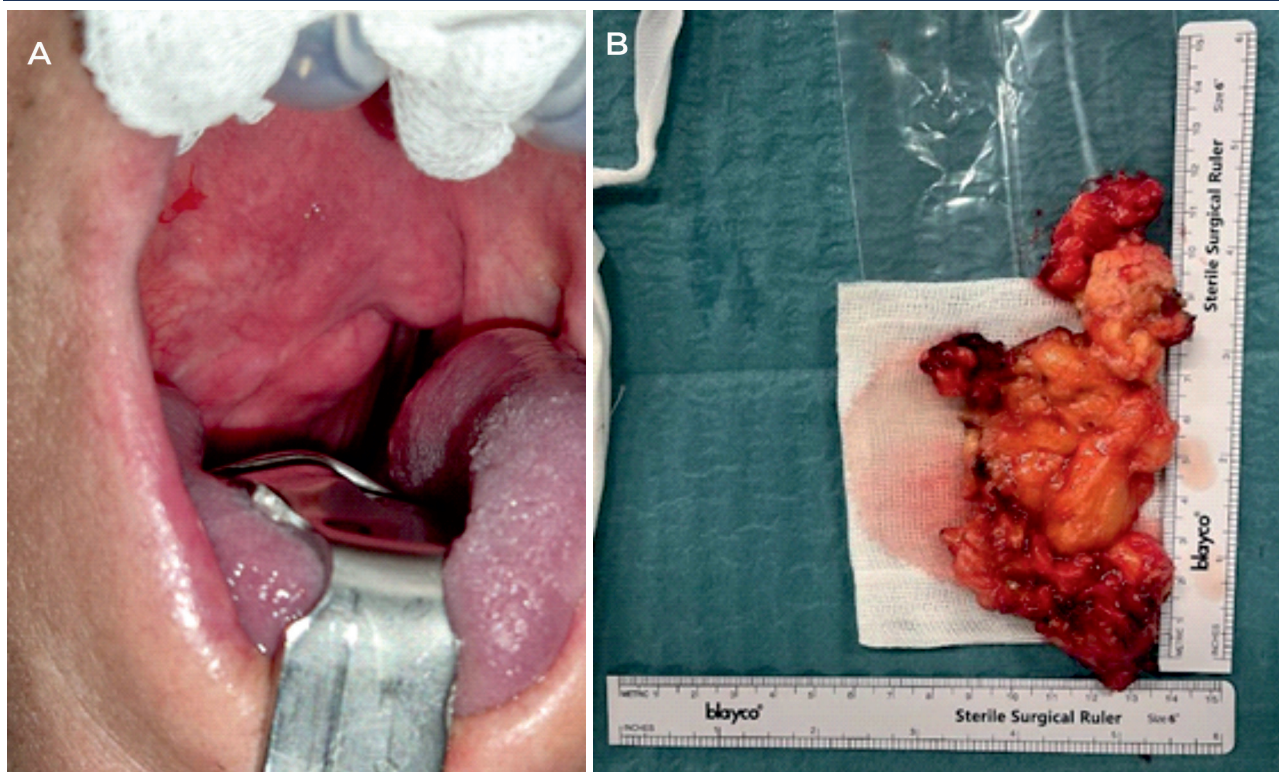
Axial (A) and coronal (B) CT scan of the neck showing a large lesion with fat density that enlarges the right parapharyngeal and retropharyngeal space 8,3 cm \* 35,5 mm \* 10 cm (transverse, anteroposterior and longitudinal)





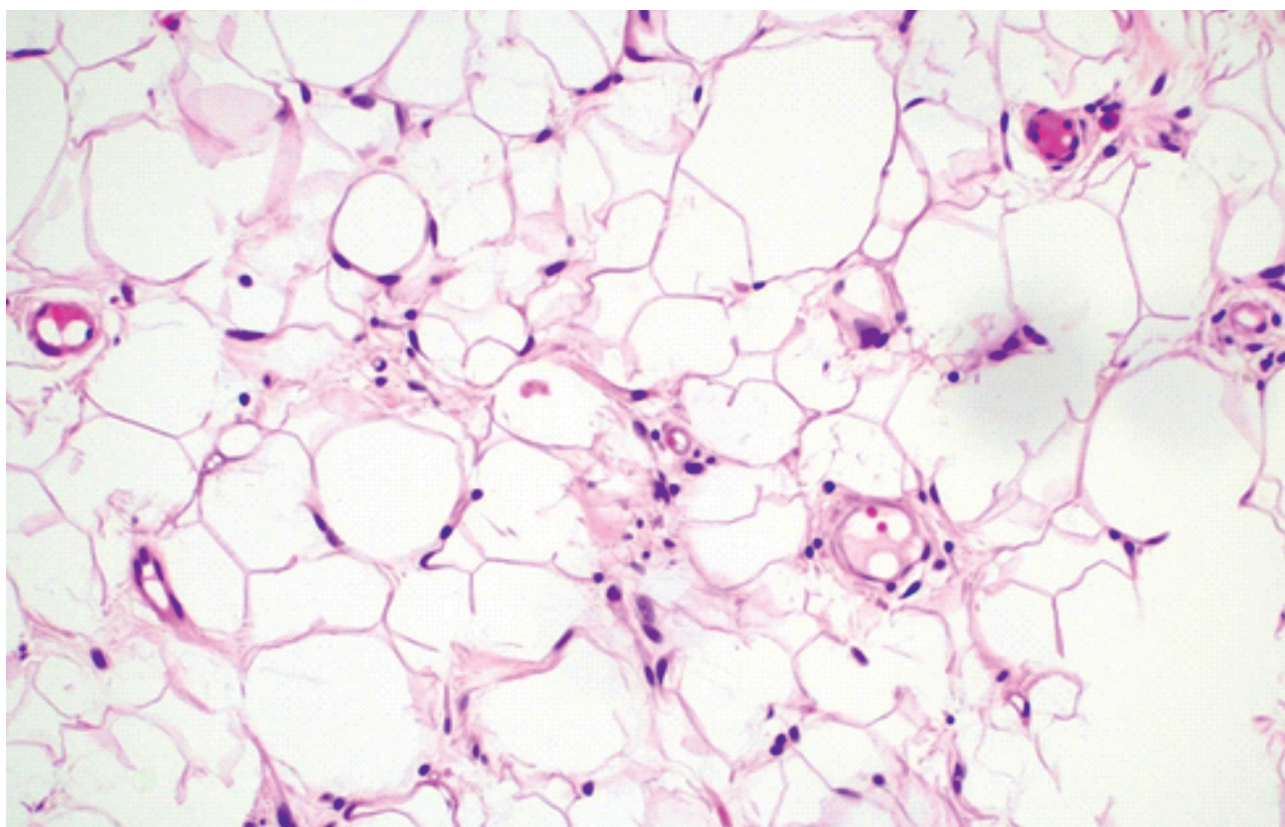
**Figure 2**

Intraoperative photograph of the lipoma and its bulge in the oropharynx (A) and (B) excised parapharyngeal lipoma 13,7 x 8 cm

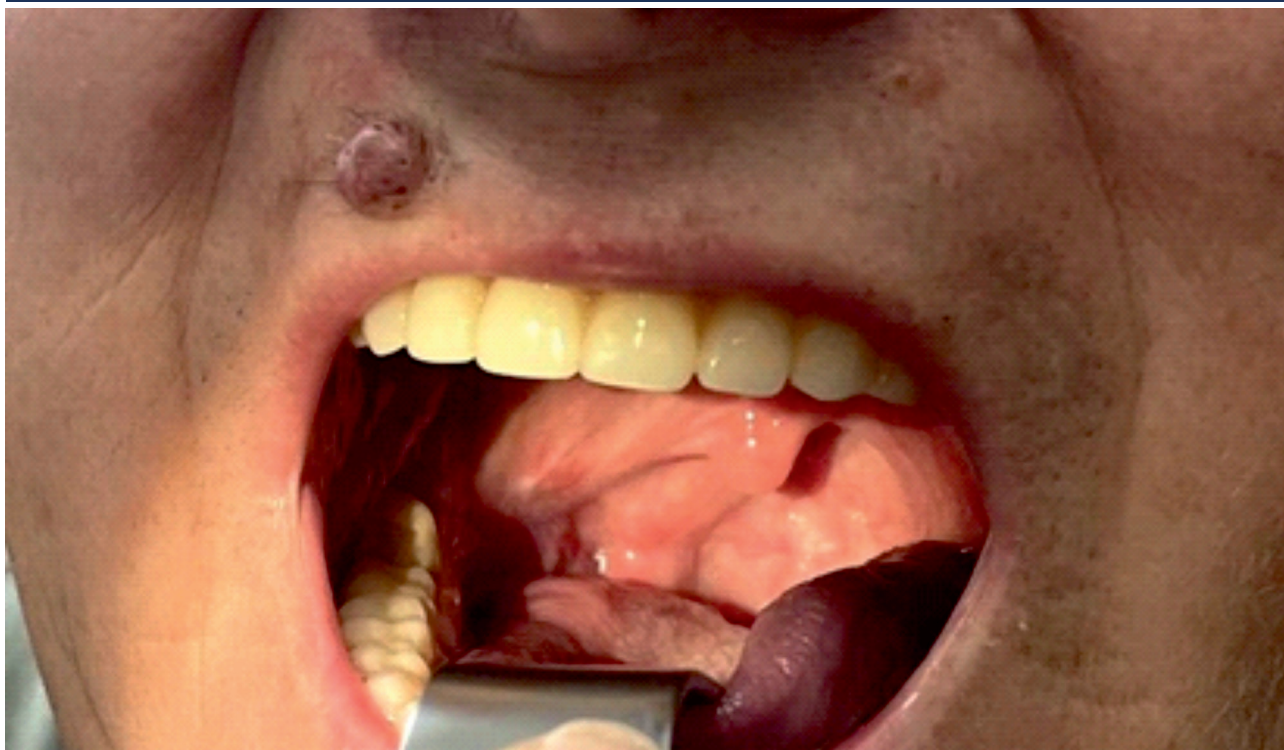

**Figure 3**

Microscopic image showing mature adipocytes (HE, 200x)



**Figure 4**  
Oropharynx at the 6-month follow-up



space. The patient underwent transoral surgical excision of the lesion, requiring both cold dissection and radiofrequency plasma dissection with minimal bleeding. There was no damage of major vascular or nervous structures and the patient was discharged 5 days post-op. The lesion was completely removed and histopathological examination confirmed the diagnosis of a lipoma.

At the 6-month follow up the patient showed significant improvement in symptoms, with complete resolution of snoring, dysphagia, and foreign body sensation.

## Discussion

Lipomas in the parapharyngeal space are extremely rare. Due to their location, they can cause significant but also indistinctive symptoms due to compression of adjacent structures.<sup>4</sup> The differential diagnosis includes other neoplasms of the parapharyngeal space, such as branchial cleft cysts, schwannomas, pleomorphic adenomas, sarcomas, among others.<sup>5</sup> Given its gradual growth, patients often seek medical attention in advanced

stages, as seen in this 69-year-old patient.

In this case, airway involvement was particularly notable, with the lesion significantly narrowing and lateralizing the airway. This raises questions about the frequency of airway compromise in parapharyngeal lipomas. According to the literature, symptoms such as progressive dysphagia, snoring, and dyspnea are considered alarm signs that should prompt investigation.<sup>6,7</sup>

Fine needle aspiration cytology (FNAC) often provides inconclusive results and may be hard to perform due to the depth of the lesions. However, imaging modalities such as CT and MRI may be able to provide a definite diagnosis.<sup>8</sup> In this case, FNAC was not performed, as imaging findings from CT scans provided a clear diagnosis based on the fat density of the lesion, reducing the necessity for invasive preoperative procedures.

Surgical resection is the treatment of choice and, when performed adequately, has an excellent prognosis, as demonstrated in this case. Lipomas of the head and neck are most commonly located in the superficial



and posterior regions of the neck, making the external approach the most frequently performed.<sup>9-11</sup> However, in this case, due to the absence of subcutaneous involvement, the extension of the lesion into the retropharyngeal space and the age of the patient, a transoral approach was preferred. This approach minimized surgical morbidity and expedited recovery, which is particularly advantageous in elderly patients. Moreover, transoral robotic surgery (TORS) has emerged as a viable alternative, offering enhanced precision and visualization for parapharyngeal space tumors, although its higher cost and need for specialized equipment limit its widespread adoption.<sup>12-14</sup>

## Conclusions

This case underlines the importance of early identification and surgical excision of parapharyngeal lipomas to prevent complications associated with tumor growth. The transoral approach, when feasible, offers a safe and effective option for resection, with minimal postoperative morbidity. Complete resection allows for symptom relief and minimizes the risk of recurrence, ensuring a successful recovery.

## Conflict of Interests

The authors declare that they have no conflict of interest regarding this article.

## Data Confidentiality

The authors declare that they followed the protocols of their work in publishing patient data.

## Human and animal protection

The authors declare that the procedures followed are in accordance with the regulations established by the directors of the Commission for Clinical Research and Ethics and in accordance with the Declaration of Helsinki of the World Medical Association.

## Privacy policy, informed consent and Ethics committee authorization

The authors declare that they have obtained signed consent from the participants and that they have local ethical approval to carry out this work.

## Financial support

This work did not receive any grant contribution, funding or scholarship.

## Scientific data availability

There are no publicly available datasets related to this work.

## References

1. Tuan HX, Tri CM, Huy NA, Duc NM. A giant parapharyngeal space lipoma. *Radiol Case Rep.* 2022 Dec 12;18(2):693-696. doi: 10.1016/j.radcr.2022.11.039.
2. Scott RF, Collins MM, Wilson JA. Parapharyngeal lipoma. *J Laryngol Otol.* 1999 Oct;113(10):935-7. doi: 10.1017/s0022215100145645.
3. Chua DY, Lim MY, Teo DT, Hwang SY. Retropharyngeal lipoma with parapharyngeal extension: is transoral excision possible? *Singapore Med J.* 2013 Sep;54(9):e176-8. doi: 10.11622/smedj.2013178.
4. Marion F, Videlaine A, Piot B, Merlet FL, Longis J, Bertin H. A giant parapharyngeal lipoma causing obstructive sleep apnea. *J Stomatol Oral Maxillofac Surg.* 2019 Dec;120(6):595-597. doi: 10.1016/j.jormas.2018.12.015.
5. Chen WL, Wang WJ, Huang ZQ, Zhang DM. Osteotomy in the vertical ramus outside the mandibular foramen for tumours in the parapharyngeal space. *J Craniomaxillofac Surg.* 2014 Apr;42(3):e29-32. doi: 10.1016/j.jcms.2013.05.008.
6. Aslan M, Ozer Ozturk E, Dogukan FM. A rare cause of dysphagia: giant lipoma in parapharyngeal space. *J Craniofac Surg.* 2020 Oct;31(7):e667-e668. doi: 10.1097/SCS.00000000000006503.
7. Luczak K, Dorobisz K, Krecicki T, Janczak D, Chabowski M, Zatonski T. The lipomatosis of the parapharyngeal and retropharyngeal space: a case report. *Srp Arh Celok Lek.* 2015 Jul-Aug;143(7-8):455-7. doi: 10.2298/sarh1508455l.
8. Pal P, Singh B, Sood AS. Unusual parapharyngeal lipoma. *Indian J Otolaryngol Head Neck Surg.* 2015 Mar;67(Suppl 1):158-60. doi: 10.1007/s12070-014-0797-0.
9. Loudghiri M, Saout Arrih B, Oukessou Y, Rouadi S, Abada R, Mahtar M. Management of a rare case of parapharyngeal lipoma presentation of case. *Int J Surg Case Rep.* 2023 May;106:108145. doi: 10.1016/j.ijscr.2023.108145.
10. Chang SS, Goldenberg D, Koch WM. Transcervical approach to benign parapharyngeal space tumors. *Ann Otol Rhinol Laryngol.* 2012 Sep;121(9):620-4. doi: 10.1177/000348941212100910.
11. Vasani A, Shah R, Hirapara K. Parapharyngeal lipoma extending to skull base: a case report with surgical approaches. *Indian J Otolaryngol Head Neck Surg.* 2024 Jun;76(3):2311-2313. doi: 10.1007/s12070-024-04488-z.
12. Hussain A, Ah-See KW, Shakeel M. Trans-oral resection

of large parapharyngeal space tumours. *Eur Arch Otorhinolaryngol.* 2014 Mar;271(3):575-82. doi: 10.1007/s00405-013-2550-9.

13. Maglione MG, Guida A, Pavone E, Longo F, Aversa C, Villano S. et al. Transoral robotic surgery of parapharyngeal space tumours: a series of four cases. *Int J Oral Maxillofac Surg.* 2018 Aug;47(8):971-975. doi: 10.1016/j.ijom.2018.01.008.

14. Mendelsohn AH. Transoral robotic assisted resection of the parapharyngeal space. *Head Neck.* 2015 Feb;37(2):273-80. doi: 10.1002/hed.23724.