

# Mediastinite descendente necrotizante - análise casuística dos últimos anos

Artigo Original

## Autores

### **Davide Lourenço Marques**

Centro Hospitalar e Universitário de Coimbra, Portugal

### **Francisca Bartolomeu**

Centro Hospitalar e Universitário de Coimbra, Portugal

### **Hugo Figueiredo**

Centro Hospitalar e Universitário de Coimbra, Portugal

### **Catarina Rato**

Centro Hospitalar e Universitário de Coimbra, Portugal

### **Sofia Paiva**

Centro Hospitalar e Universitário de Coimbra, Portugal

### **António Miguéis**

Centro Hospitalar e Universitário de Coimbra, Portugal

### **Jorge Miguéis**

Centro Hospitalar e Universitário de Coimbra, Portugal

### **Correspondência:**

Davide Lourenço Marques  
davide.marques@edu.uisboa.pt

Artigo recebido a 1 de Agosto de 2024.

Aceite para publicação a 24 de Outubro de 2024.

## Resumo

**Objetivos:** Descrever a experiência dos últimos 3 anos num hospital terciário, abordando as atitudes terapêuticas, resultados e complicações.

**Métodos:** estudo retrospectivo descritivo, desde novembro de 2019 até dezembro de 2022, onde avaliámos 7 doentes diagnosticados com MDN, fazendo a análise da idade, sexo, subtipo da doença, origem da infeção, comorbilidades, intervenções cirúrgicas, duração do internamento, microrganismos isolados e quadro clínico.

**Resultados:** Todos os doentes foram submetidos a cirurgia para drenagem das coleções e desbridamento cirúrgico. A maioria dos doentes (85,7%) foi tratada cirurgicamente com drenagem transcervical combinada com drenagem transtorácica. Apenas um doente foi submetido a abordagem cirúrgica transcervical isolada. Foram relatados 5 casos (71,4%) em que houve necessidade de reoperação / revisão cirúrgica. A realização de traqueotomia foi feita em 57,1% dos casos. A duração média de internamento hospitalar foi de 52,1 33,6 dias (intervalo: 23-120 dias), enquanto a duração média de internamento em unidade de cuidados intensivos foi de 22 26,6 dias (intervalo: 2-77 dias). Não se registaram casos de morte durante a permanência hospitalar e apenas 1 doente teve uma complicação major, nomeadamente imobilidade laríngea bilateral, com necessidade de traqueostomia permanente. Os restantes doentes tiveram alta para ambulatório com evolução favorável.

**Conclusão:** De forma a melhorar o prognóstico da MDN, é essencial o desbridamento cirúrgico precoce e adequado das áreas afetadas, associado ao uso de antibióticos e/ou antifúngicos dirigidos. Uma abordagem multidisciplinar envolvendo a Cirurgia Cardiorádica e a Otorrinolaringologia é indispensável para o tratamento desta condição.

**Palavras-chave:** Mediastinite descendente necrotizante, drenagem transcervical, drenagem transtorácica; , cirurgia torácica videoassistida

## Introduction

Descending Necrotizing Mediastinitis (DNM) is an uncommon but rapidly progressive and potentially life-threatening type of mediastinitis. This infection commonly originates in the head and neck region and its progression involves the extension through deep fascial planes, ultimately descending into the mediastinal region.<sup>1</sup> While historical mortality rates were notably elevated, reaching up to 40%, recent advancements have led to a considerable reduction, with an overall reported mortality rate of 17.5%.<sup>2</sup> This decline is attributed to the widespread administration of antibiotics and enhancements in diagnostic, surgical, and interdisciplinary management approaches.<sup>3</sup>

DNM may originate in cases of odontogenic (36% to 47%), pharyngeal (33% to 45%), cervical (15%), and other head and neck infections (5%). This is particularly evident in instances of cervical necrotizing fasciitis that extends directly or from the parapharyngeal space to regions bounded by fascia communicating with the mediastinum. Approximately 8% of cases originate from the pretracheal/paraesophageal space (extended up to the carina), 12% from the carotid space, and around 70% from the prevertebral/retropharyngeal space (extended up to T3) or the "dangerous" space (extended up to the diaphragm through the posterior mediastinum).<sup>4</sup>

Diagnostic criteria for DNM, as established by Estrera et al.<sup>1</sup> include: (1) clinical manifestations of severe infection; (2) demonstration of characteristic radiographic findings; (3) documentation of necrotizing mediastinal infection during surgery or autopsy; and (4) confirmation of the relationship between oropharyngeal/cervical infection and descending necrotizing mediastinitis.

Regarding the pathway of mediastinal infection, Endo et al.<sup>5</sup> proposed a classification system based on the extent of mediastinal involvement: type I denotes infection localized to the upper mediastinum above the carina; type IIa indicates infection extending to the lower anterior mediastinum and type

IIb refers to infection extending to both the anterior and posterior mediastinum. To date, this classification has been effectively applied in practical usage, however DNM is relatively uncommon in clinical practice, leading to limited experience in its management within individual medical institutions.<sup>6</sup>

Recently, studies conducted by Sugio et al.<sup>7</sup> have proposed a new classification for DNM, introducing type IIc, localized only within the posterior mediastinum. This classification reveals distinct prognostic implications based on the location of infection extension within the mediastinum. Additionally, it defines different surgical approaches tailored to each DNM subtype.<sup>7</sup>

The clinical diagnosis is often delayed due to nonspecific symptoms until there is evident clinical deterioration. Confirmation is typically achieved through cervical-thoracic computed tomography (CT).<sup>4,8</sup> CT serves as a gold standard diagnostic tool for clinical diagnosis, determining the extent of mediastinal involvement and additionally it functions as a reference point for postoperative monitoring and assessment.<sup>2</sup>

In 58% of cases (30% to 75%), DNM manifests as a polymicrobial infection. Predominantly, gram-positive bacteria, notably *Streptococcus* (ranging from 43% to 62%), and anaerobic bacteria (ranging from 46% to 78%) are implicated. Gram-negative Enterobacterias, such as *Klebsiella*, are less frequently involved (4% to 8%), except in cases of patients with diabetes.<sup>4,9</sup>

Severe complications associated with a high mortality rate in DNM include multiple organ dysfunction syndrome, sepsis, or septic shock.<sup>4,10</sup>

Descending necrotizing mediastinitis demands a comprehensive, multidisciplinary approach, primarily centered around surgical debridement. The optimal extent of debridement remains a subject of contention, with discussions surrounding the choice between solely transcervical or incorporating routine transthoracic thoracotomy.<sup>4,8</sup> Recently, there have been reports of less

invasive drainage methods for DNM, such as Video-Assisted Thoracic Surgical drainage (VATS), mediastinoscopy, and percutaneous catheter drainage.<sup>11</sup> Medical intervention is characterized by the administration of broad-spectrum antibiotics, designed to target gram-positive and anaerobic bacteria, and, in cases involving diabetes, gram-negative bacteria. The therapeutic strategy also entails prolonged care within the intensive care unit (ICU), emphasizing the critical role of ongoing monitoring and support in achieving favorable patient outcomes.

Although it is certain that early control of the source of infection and drainage are crucial for the treatment and prognosis of DNM, as this is a rare entity, there are no guidelines regarding surgical treatment. In this case analysis, the clinical characteristics and treatment of DNM in our hospital center were discussed to add more data to the literature.

## Material and Methods

We conducted a retrospective study encompassing 7 patients diagnosed with DNM in our hospital from November 2019 to December 2022. Diagnostic criteria, as established by Estrera et al., guided the assessment. Patient demographics, disease subtypes, infection sources, comorbidities, surgical interventions, length of hospital stay, isolated microorganisms, and clinical outcomes were systematically reviewed. Preoperative CT scans were employed for diagnosis confirmation, and post-surgical follow-up was conducted. The categorization of DNM types followed the criteria proposed by Sugio et al., representing the most recent classification in the literature.

## Data Analysis

Statistical analysis was conducted utilizing SPSS version 29.0. Data were presented as the mean  $\pm$  standard deviation.

## Results

Despite the non-specific symptoms in DNM, all patients presented symptoms

compatible with pharyngeal infection and the development of respiratory symptoms, such as dyspnea or chest discomfort, combined with radiological findings.

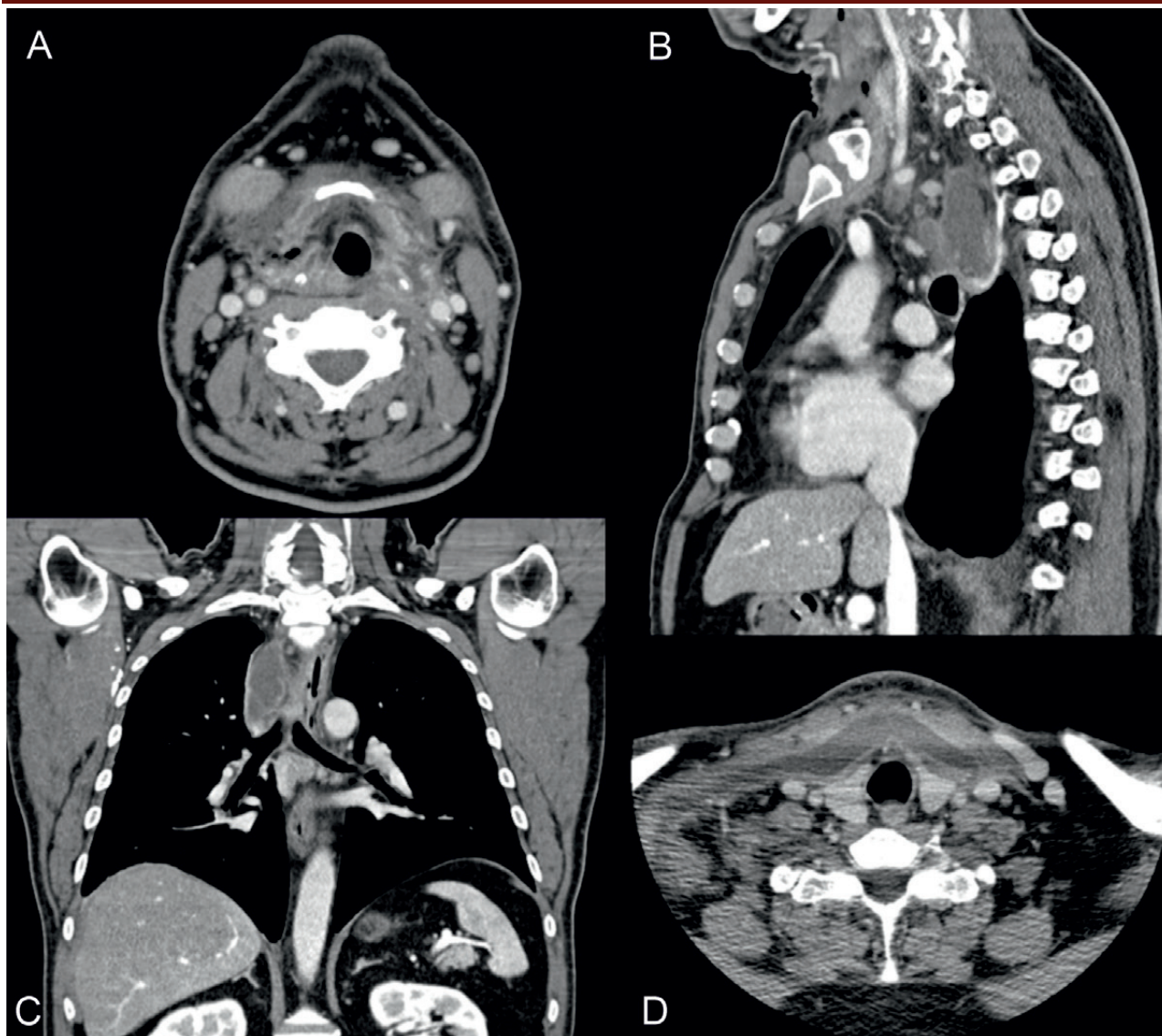
In terms of gender distribution, 4 (57.1%) patients were female and 3 (42.9%) male patients, with a mean age of 66.14  $\pm$  9.26 years (range 53-80 years). Regarding comorbidities, of these 7 patients, 3 patients (42.9%) did not exhibit any relevant comorbid conditions, 2 patients had chronic heart disease, and there was also the presence of diabetes mellitus (n=1), obesity (n=1), hypothyroidism (n=1) and chronic obstructive pulmonary disease (n=1). The primary origin of the infection was parapharyngeal abscesses in the majority of cases (71.4%; n=5), followed by peritonsillar and retropharyngeal abscesses, each with a frequency of 14.3% (n=1). Following the DNM classification proposed by Sugio et al, our patient cohort consisted of 2 individuals classified as Type I (28.6%) and 5 individuals classified as Type II (71.4%). Within the Type II category, 2 patients (28,6%) were further classified as Type IIa and Type IIb each, and 1 patient (14,2%) was classified as Type IIc. Below, we present characteristic imaging findings for each subtype of descending necrotizing mediastinitis in Figures 1, 2, 3 and 4.

Blood tests and microbiological assessments of pus and tissues were carried out for all subjects in the study. Broad-spectrum antibiotics were initiated immediately upon their admission to the hospital, and subsequent adjustments were made based on the specificities derived from the culture results. The average duration of intravenous antibiotic therapy was 33.57 days ( $\pm$  8.44 days). Microorganisms were isolated in 5 of the patients studied, identifying combinations of gram positive and negative agents with anaerobic agents. In two of these 2 cases, fungi were isolated at the same time. No microorganisms were isolated from the remaining patients. The frequencies of the identified agents are shown in table 1.

All patients underwent surgery for drainage of collections and surgical debridement. The majority of patients (85.7%) underwent

**Figure 1**

Computed tomography of the neck and chest of a patient classified with descending necrotizing mediastinitis, type I. An extensive cervical abscess is observed, extending anteriorly and distally from the pharyngeal mucosal space in the topography of the palatine tonsils (especially on the right), anteriorly to the thyroid with extension to the superior mediastinum. On the right side of the superior mediastinum, mostly in right paratracheal topography, an abscedate collection is evident, which is in apparent contact with the cervical abscess, with 6x2cm in longest axial axes and at least 10cm in longitudinal extension. Gas bubbles are also identified in the superior mediastinum with fat densification, aspects compatible with necrotizing descending mediastinitis.

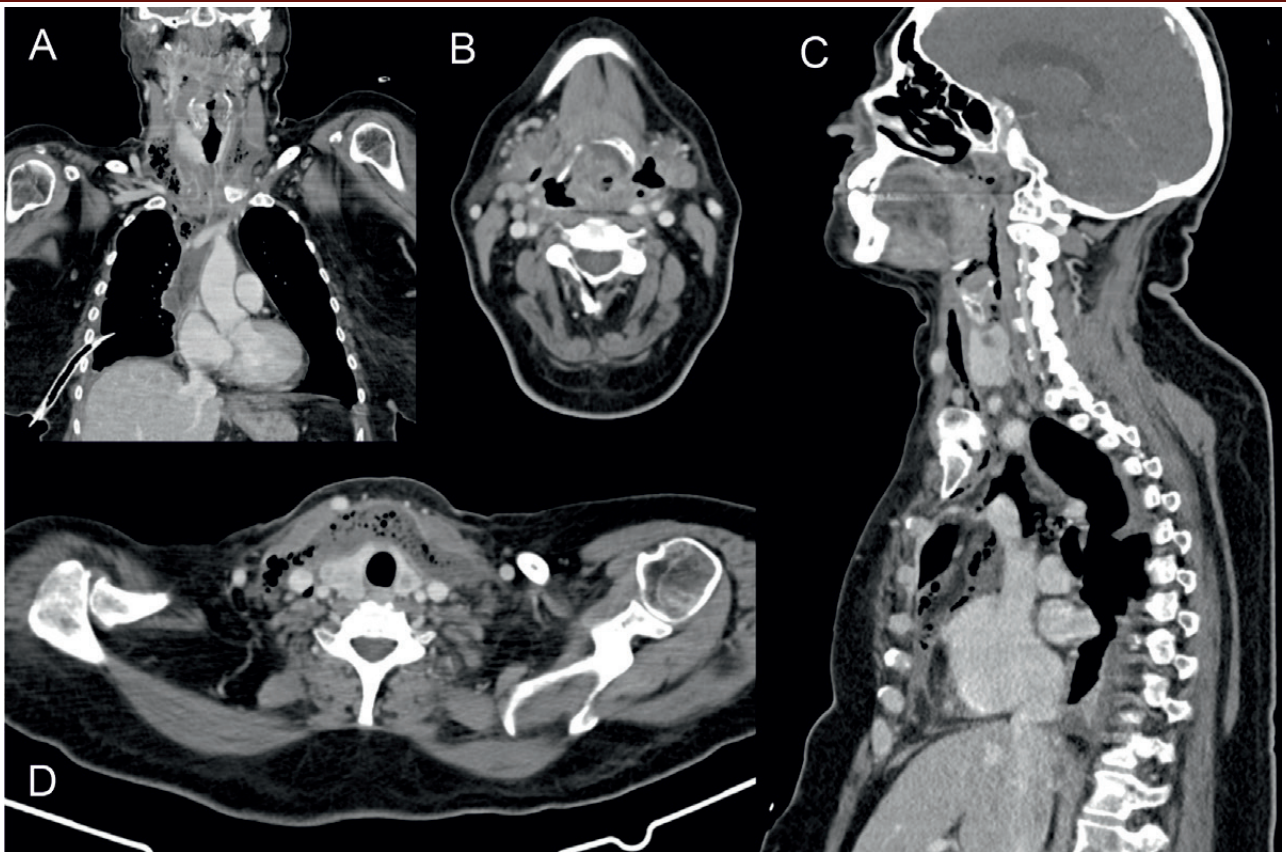


combined transcervical and transthoracic drainage. Only one patient underwent isolated transcervical surgical approach. Five cases (71.4%) required reoperation/surgical revision. Tracheostomy was performed in 57.1% of cases. The average hospitalization duration was  $52.1 \pm 33.6$  days (range: 23-120 days), while the average intensive care unit stay was  $22 \pm 26.6$  days (range: 2-77 days). All patients were

referred to rehabilitation programs. No deaths occurred during hospitalization, and only one patient experienced complications, namely pneumonia and bilateral vocal cord immobility, requiring permanent tracheostomy. The remaining patients were discharged with a favorable outcome. The clinical characteristics of the patients and the surgical approaches are summarized in table 2.

**Figure 2**

Computed tomography of the neck and chest of a patient classified as necrotizing descending mediastinitis, type IIa. Emphysema of the bilateral parapharyngeal spaces is observed, beginning at the level of the oropharynx, extending to the region of the hypopharynx, embracing it practically in 360 degrees, extending inferiorly to the superior and anterior mediastinum, local where some liquid, unorganized accumulation is also observed.



**Table 1**

Microbiological evaluation of patients with descending necrotizing mediastinitis

**Microbiological isolation of the study population**

**Bacterial agents**

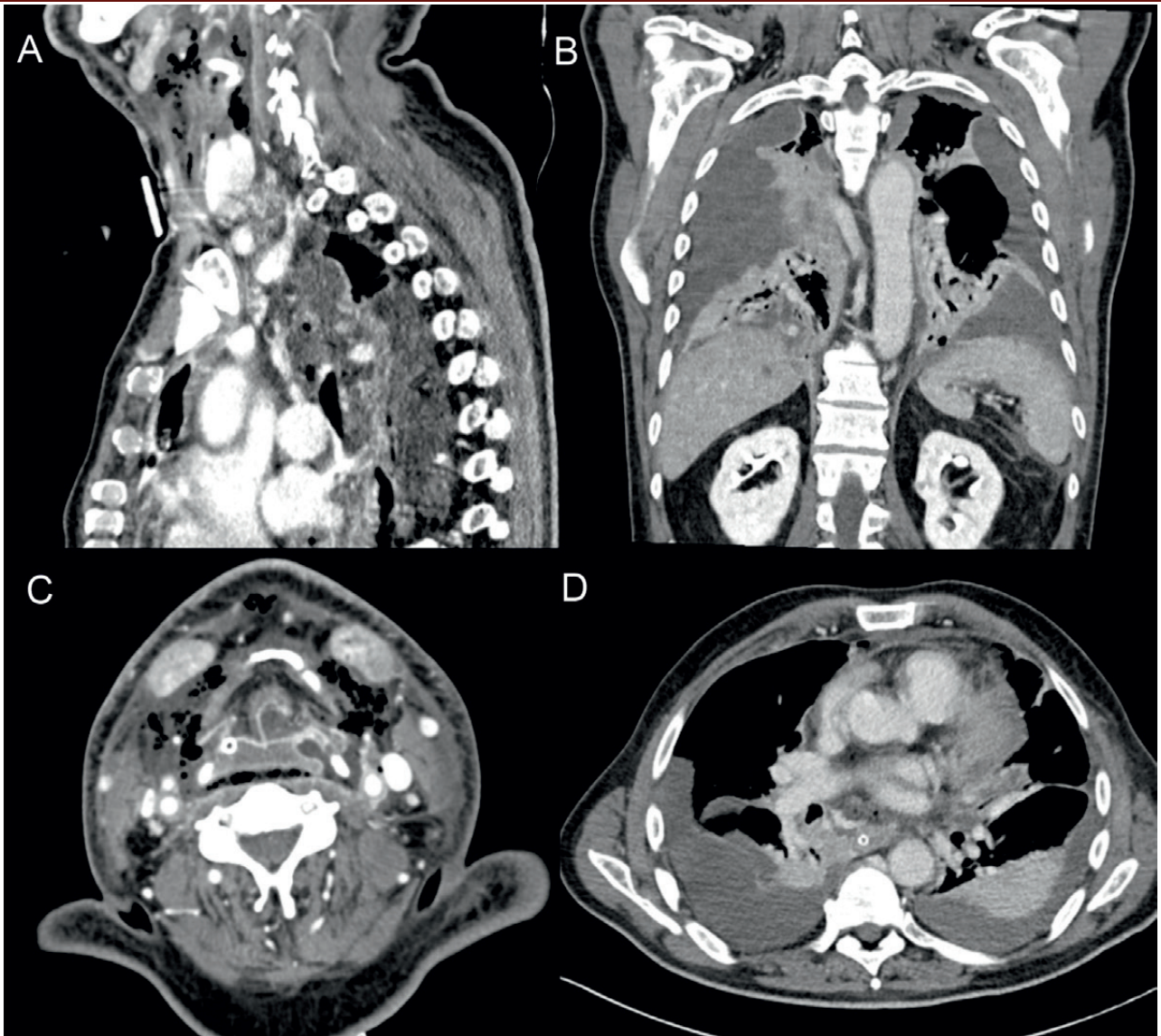
- Streptococcus constellatus spp pharyngis (n=3)
- Staphylococcus epidermidis (n=2)
- Parvimonas micra (n=2)
- Prevotella spp (n=2)
- Viridans Streptococcus Group (n=1)
- Staphylococcus warneri (n=1)
- Eikenella corrdens (n=1)
- Fusobacterium nucleatum (n=1)
- Escherichia Coli (n=1)
- Acinetobacter pittii (n=1)
- Veilonella párvula (n=1)

**Fungal agentes**

- Candida parapsilosis (n=1)
- Candida albicans (n=1)

### Figure 3

Computed tomography imaging of the neck and chest reveals a patient with necrotizing descending mediastinitis, classified as type IIb. There is an organized collection originating from the oropharynx, extending posteriorly through the retropharyngeal space into the mediastinum, encircling it completely. The collection continues downward along the right lateral aspect of the esophagus, with apparent extension to the right hilar region, and terminates around the esophageal hiatus. Within the cervical region, the collection contains both liquid and gaseous components, accompanied by significant edema of the surrounding soft tissues. Furthermore, there is bilateral pleural effusion, showing signs of organization, and associated with consolidation of the adjacent lung parenchyma.



### Discussion

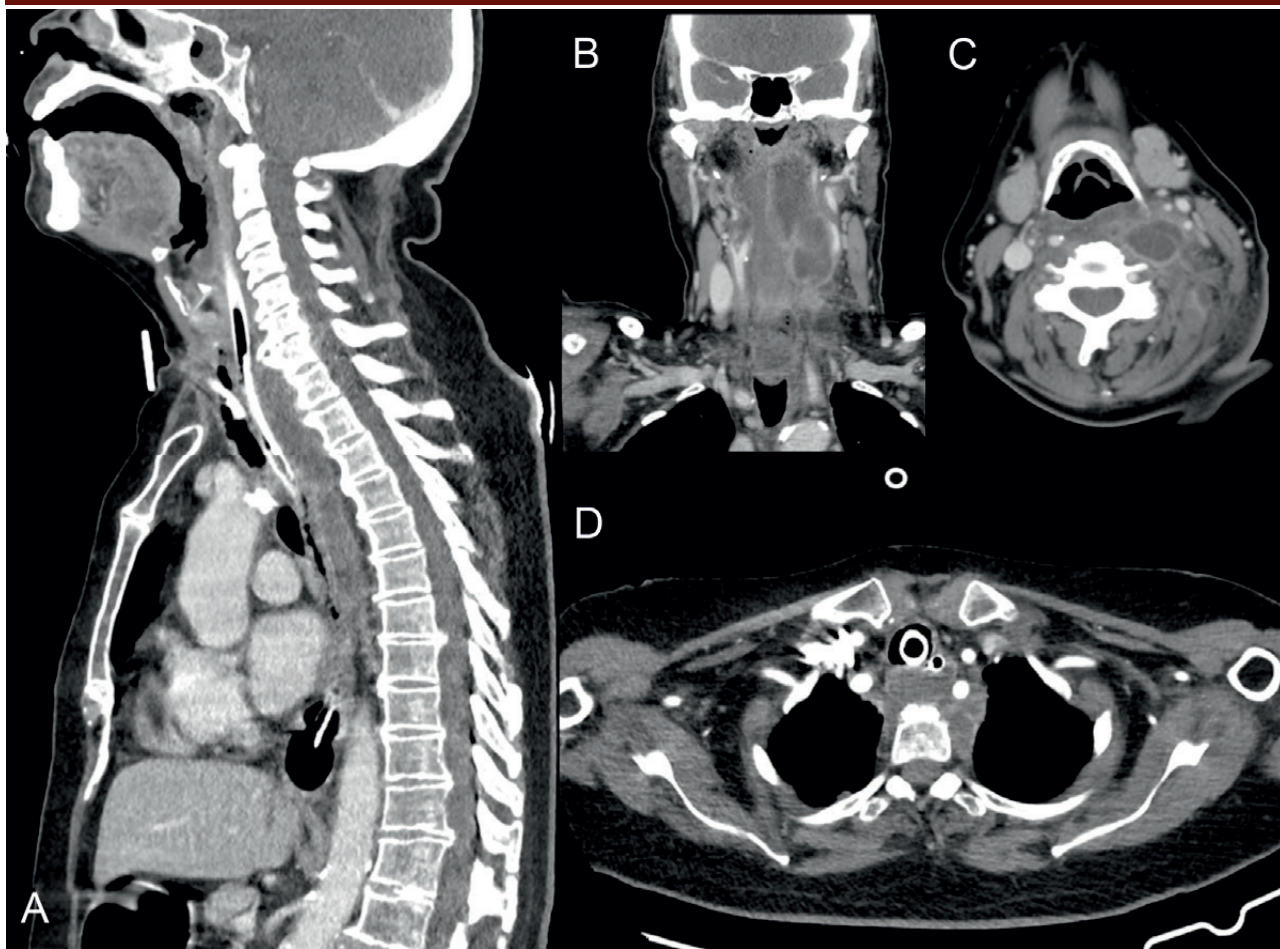
DNM is a rare yet potentially lethal condition resulting from infections originating in the odontogenic, pharyngeal, or cervical regions. The disease progresses into the mediastinum through the anatomical cervical fascial planes, specifically involving the retropharyngeal, pretracheal, and paraesophageal planes. This pathology poses a significant threat to life

due to its aggressive nature and potential for severe complications. Consensus in the existing literature underscores the critical importance of early-stage diagnosis for DNM, coupled with the timely commencement of suitable medical interventions and radical surgical treatments.

Regarding demographic aspects, in our study, 57.1% of patients were female and 42.8% were

**Figure 4**

The computed tomography scan of the neck and chest of a patient diagnosed with necrotizing descending mediastinitis, specifically classified as type IIc, reveals a complex condition. A multiloculated retropharyngeal abscessed collection is evident, extending from the nasopharynx to the mediastinum and descending below the carina. Numerous gas bubbles are observed posterior to the left sternocleidomastoid muscle within the subcutaneous cellular tissue. In the nasopharynx, the abscess is predominantly situated on the left side, posterior to the jugulocarotid axis at approximately the level of the epiglottis. It crosses the midline, involving muscles on the right side as well, and extends posteriorly to the esophagus toward the mediastinum.



male, and these data contradict the majority of studies, which indicate that there is a small predisposition to this condition among males.<sup>7</sup> The average age of patients with DNM in our study was 66.14 years, with an age range between 53 and 80 years. In fact, the literature reveals that this entity is more common after 60 years of age (64% of cases), while 30% of patients are aged between 40 and 50 and 6% are under 40 years.<sup>7</sup> There are also rare cases described in pediatric ages.<sup>12</sup>

The main causes of DNM are odontogenic infections, tonsillar and pharyngeal abscesses, sialadenitis, foreign body injury or

catheterization. The primary origin of DNM is unknown in some cases. In our study, only pharyngeal foci were found. The explanation may be because these were patients who were referred to the Otorhinolaryngology Department, with the other cases perhaps being sent to other specialties such as Stomatology or Maxillofacial surgery. Within the pharyngeal foci, in our study, the main source of infection was parapharyngeal abscesses in 71.4% of cases (n=5), followed by peritonsillar and retropharyngeal abscesses. The initial signs and symptoms of DNM universally manifest as mild and nonspecific.

**Table 2**  
Clinical characterization of patients and surgical approaches

Case	Gender	Age	DNM type	Origin of infection	Empirical antibiotic therapy	Surgical intervention	Number of operations	Traqueotomy
1	Male	53	I	Parapharyngeal abscess	Piperacillin-tazobactam + metronidazole	Transoral + Transcervical + Triportal right VATS	2	No
2	Female	63	I	Parapharyngeal abscess	Ceftriaxone + metronidazole + vancomycin	Transoral + Transcervical	1	No
3	Male	64	Ila	Parapharyngeal abscess	Piperacillin-tazobactam + clindamycin + vancomycin	Transoral + Transcervical + Triportal right VATS	1	No
4	Female	67	Ila	Parapharyngeal abscess	Ceftriaxone + metronidazole	Transoral + Transcervical + Biportal VATS + Uniportal VATS	3	Yes
5	Female	60	IIb	Parapharyngeal abscess	Ceftriaxone + metronidazole	Transoral + Transcervical + Left Triportal VATS + Right Thoracotomy	3	Yes
6	Male	76	IIb	Peritonsillar abscess	Ceftriaxone + metronidazole + vancomycin	Transoral + Transcervical + Left thoracotomy	3	Yes
7	Female	80	IIc	Retropharyngeal abscess	Ceftriaxone + clindamycin + vancomycin	Transoral + Transcervical + Triportal right VATS	2	Yes

Abbreviations: DNM - Descending Necrotizing Mediastinitis; VATS - Video-assisted thoracoscopic surgery.

Clinical signs associated with cervical localization include pain, dysphagia, anorexia, dyspnea, tachypnea, fever, odynophagia, hoarseness, erythema, anterior neck edema, and crepitus. Diagnosing DNM can be challenging due to the non-specific nature of these symptoms. Symptoms indicative of mediastinal infection encompass chest discomfort, respiratory insufficiency, and the manifestation of septic signs.<sup>11</sup>

A considerable proportion of individuals diagnosed with DNM exhibit immunocompromised states and concurrent comorbidities such as diabetes mellitus, malnutrition, renal failure, liver cirrhosis, and underlying malignancies. Notably, a subset of DNM cases (28.1%) lacks identified comorbidities.<sup>11</sup> In our review, the main comorbidity identified was chronic heart disease, followed by diabetes mellitus, obesity, hypothyroidism, and chronic lung disease, with no comorbidity identified in 43% of

cases. Factors associated with the mediastinal progression of DNM in cervicofacial necrotizing fasciitis patients have been investigated. Predictive factors for mediastinal spread include age, comorbid conditions (particularly diabetes), pharyngeal origin, pre-hospitalization, oral glucocorticoid usage, gas production by the infecting organism, and the extent of involvement of spaces, notably the retropharyngeal space.<sup>13,14</sup>

The microbiological findings exhibit complexity and polymicrobial nature, characterized by the presence of both aerobic and anaerobic organisms, resembling the composition of the oral microbiome. Among the aerobic bacteria, *Streptococcus* species (*S. constellatus*, *S. intermedius*, *S. agalactiae*, *S. mitis*) are frequently encountered. Common anaerobic bacteria include *Peptostreptococcus*, *Bacteroides fragilis*, *Prevotella*, and *Fusobacterium*.<sup>11</sup> In our analysis, *Streptococcus constellatus* spp *pharyngis* were the most



prevalent, as shown in Table 1. Of particular significance was the detection of fungi in two instances, highlighting once more the polymicrobial aspect of such infections, corresponding in all cases to the isolation of the *Candida spp* group. Notably, other conducted studies have similarly identified fungal organisms.<sup>7,15</sup> Bacterial cultures were negative in 2 patients, possibly due to prior antibiotic treatment before admission, as happened in other investigations carried out.<sup>2</sup> Computed tomography scanning stands as the gold standard for the early detection and diagnosis of DNM. It enables precise assessment of the infection's extent, facilitates diagnosis, and assists in surgical planning.<sup>16</sup> Characteristics of DNM include widespread thickening of the skin and subcutaneous tissues, reticular enhancement of the subcutaneous fat, thickening and enhancement of cervical fasciae, platysma, muscles, and mediastinal fat, subcutaneous gas, fluid collections, pericardial effusion, and pleural effusion (Figures 1, 2, 3 and 4).<sup>11</sup> Identifying the continuity of infection from the neck to the thorax is crucial for diagnosing DNM. Understanding the route of mediastinal extension is essential for establishing effective drainage. As previously indicated, CT scanning allows for the classification of DNM types. As described by Sugio et al, our study revealed one case where infection affected only posterior mediastinum. Consequently, we agree with Sugio's classification proposal with subdivision of type II into type IIa, IIb, and IIc. We recommend too postoperative CT scans of the neck and thorax within 48 to 72 hours or in case of clinical deterioration to ascertain the need for reoperation.

Upon diagnosis of DNM, it is crucial to admit the patient to the ICU for continuous monitoring and management of sepsis. Alternatively, if the current medical facility lacks the resources for intensive care, the patient should be promptly referred to a facility equipped to provide the necessary critical care.<sup>11</sup>

Antibiotic therapy should be initiated promptly. Given the frequently polymicrobial

nature of DNM, antibiotics must possess broad-spectrum activity against Gram-positive, Gram-negative, and anaerobic bacteria. Several empiric antibiotic regimens have been outlined in literature, including combinations such as piperacillin-tazobactam with vancomycin, or clindamycin with ceftriaxone or carbapenems.<sup>11</sup> In our review, ceftriaxone, metronidazole and vancomycin were the most commonly used antibiotics (Table 2). Antibiotic therapy should be tailored as cultures and sensitivities become available. For the microbiological positivity for fungi, anti-fungal drugs were also used, in particular caspofungin and anidulafungin. The optimal duration of antibiotic therapy for DNM remains to be firmly established. The average duration of intravenous antibiotic therapy in our study was 33.57 days. Current consensus suggests a treatment duration ranging between 14 and 21 days. However, if complications arise, the course may need to be extended.<sup>17</sup>

Antibiotic treatment alone is inadequate for effectively managing DNM, which carries a substantial mortality rate (55%-86%).<sup>8</sup> Early surgical intervention by Otolaryngologists and Cardiothoracic surgeons is crucial. The choice of surgical approach is dictated by the specific type of DNM, with consensus suggesting that drainage of both the primary infection site and the mediastinum is essential. Cervical drainage in the affected area is unequivocal. Nevertheless, the most effective method for mediastinal drainage remains a subject of controversy. There is considerable variation in the approaches employed for mediastinal drainage, including thoracotomy, median sternotomy, clamshell incision, subxiphoid approach, transcervical approach, VATS, mediastinoscopy, and percutaneous catheter drainage.<sup>11</sup> Endo et al. proposed that the choice of surgical drainage approach should be based on the extent of mediastinal infection. They suggested that type I DNM may not necessitate aggressive mediastinal drainage and that a transcervical approach could be sufficient for infection control. For type IIa, subxiphoidal mediastinal drainage without

sternotomy might provide adequate drainage, while type IIb typically requires complete mediastinal drainage via thoracotomy. Palma et al. reported successful infection control using a similar strategy in their series.<sup>5,9</sup> On the other hand, Sugio et al demonstrated that type IIc patients do not require such aggressive interventions, revealing that they predominantly undergo VATS (41.9%), with less need for thoracotomy (20.9%) and transcervical approach (34.9%).<sup>7</sup> Patients with type I and IIc infections were more likely to undergo cervical drainage compared with patients with type IIa and IIb infections (34.3% and 13.4%, respectively). On the other hand, thoracotomy was used more frequently for type IIa and IIb infections compared to type I and IIc (42.6% and 16.7%, respectively).<sup>7</sup> This difference in terms of surgical approach and prognosis demonstrates the need for a new classification with the introduction of type IIc. Indeed, in our study, consistent with the findings of Sugio et al., patients with DNM subtypes I and IIc were managed primarily with transcervical surgical drainage and video-assisted thoracoscopic surgery (VATS), with thoracotomy being reserved for cases of DNM type IIb. Isowa et al. were the first to report the successful management of DNM patients using video-assisted thoracic surgery.<sup>18</sup> Subsequently, more authors began advocating for VATS as a treatment option for DNM, highlighting its excellent visualization of the entire thoracic cavity, minimal invasiveness, and favorable outcomes. The universal advantages of minimally invasive surgery, such as reduced postoperative pain, improved cosmetic outcomes, and faster recovery times, are also inherent to the VATS technique.<sup>11</sup> However, the use of VATS provides limited access to the mediastinum, which can restrict the surgeon's ability to completely excise all affected necrotic tissue. Therefore, VATS is recommended to be utilized in selected cases.<sup>16</sup> In our study, VATS was performed in 5 out of 7 patients (1 with type I DNM, and 4 with type II DNM) because it offered a minimally invasive approach to drainage of mediastinal

and pleural collections. However, in one patient with type IIb DNM, VATS was insufficient as an initial approach, necessitating subsequent conversion to thoracotomy. All our patients underwent transoral drainage of the initial foci and a transcervical approach. In our study, 5 of the 7 patients required reoperations, especially patients with subtypes IIa and IIb. In subtypes I and IIc, reoperation was required because transoral drainage of the initial abscess was performed during primary surgery.

Tracheotomy is recommended for patients with airway compromise or those requiring long-term treatment. However, its routine application is contentious due to the potential risk of cervical infection contamination. In our study, only 4 out of 7 cases underwent tracheotomy, specifically among patients with type II (type IIa, n=1; type IIb, n=2; type IIc, n=1). Frequently encountered are complications of the disease, with a range spanning from 45% to 70%. Notably, these include pneumonia (25%), airway obstruction, jugular vein thrombosis, suppurative jugular thrombophlebitis (Lemierre's syndrome), carotid artery erosion and rupture, septic shock, cranial nerve paralysis, empyema, and bronchocavitary fistula. Conversely, complications stemming from surgical interventions are less common, observed in around 12% of cases.<sup>3,11</sup> In our case analysis, a patient diagnosed with DNM type IIb experienced significant complications (14%). These included ventilator-associated pneumonia and recurrent paralysis of the nerves, leading to bilateral immobility of the larynx and necessitating a permanent tracheotomy. Patients diagnosed with DNM exhibit a prolonged hospitalization period, averaging 25 days (range: 15–60 days).<sup>3</sup> In our study, the average length of hospital stay was  $52.1 \pm 33.6$  days, while the average length of stay in the intensive care unit was  $22 \pm 26.6$  days. No instances of mortality were documented during the hospitalization period, consistent with recent literature indicating progressively diminishing mortality rates attributed to advancements in early detection and interventions.

## Conclusion

Although rare, descending necrotizing mediastinitis presents as an acute and potentially life-threatening condition. Computed tomography serves as the gold standard for early detection, guiding surgical interventions effectively. The classification of DNM subtypes by Endo et al. is considered oversimplified, prompting a more nuanced subdivision of type II into subtypes IIa, IIb, and IIc, as proposed by Sugio et al. in 2021, reflecting differences in severity, therapeutic approaches, and prognosis. To enhance DNM prognosis, thorough surgical debridement of affected regions, coupled with targeted antibiotic and/or antifungal therapy, and intensive care are crucial. A multidisciplinary approach involving Cardiothoracic Surgery and Otorhinolaryngology is essential for comprehensive management, with video-assisted thoracic surgery showing promise in specific cases. Routine tracheotomy may not be warranted for all patients, underscoring the importance of individualized treatment strategies.

## Conflict of Interests

The authors declare that they have no conflict of interest regarding this article.

## Data Confidentiality

The authors declare that they have followed the protocols of their work in the publication of patient data.

## Protection of People and Animals

The authors declare that the procedures followed are in accordance with the regulations established by the directors of the Clinical and Ethics Investigation Committee and in accordance with the Declaration of Helsinki of the World Medical Association.

## Privacy Policy, Informed Consent, and Ethics Committee Authorization

The authors declare that they have written consent for the use of patient photographs in this article.

## Funding

This work did not receive any contribution, funding, or scholarships.

## Availability of Scientific Data

There are no publicly available datasets related to this work.

## Bibliography

1. Estrera AS, Landay MJ, Grisham JM, Sinn DP, Platt MR. Descending necrotizing mediastinitis. *Surg Gynecol Obstet.* 1983 Dec;157(6):545-52.
2. Reuter TC, Korell V, Pfeiffer J, Ridder GJ, Ketterer MC, Becker C. Descending necrotizing mediastinitis: etiopathogenesis, diagnosis, treatment and long-term consequences - a retrospective follow-up study. *Eur Arch Otorhinolaryngol.* 2023 Apr;280(4):1983-1990. doi: 10.1007/s00405-022-07769-x.
3. Prado-Calleros HM, Jiménez-Fuentes E, Jiménez-Escobar I. Descending necrotizing mediastinitis: systematic review on its treatment in the last 6 years, 75 years after its description. *Head Neck.* 2016 Apr;38 Suppl 1:E2275-83. doi: 10.1002/hed.24183.
4. Kocher GJ, Hokschi B, Caversaccio M, Wiegand J, Schmid RA. Diffuse descending necrotizing mediastinitis: surgical therapy and outcome in a single-centre series *Eur J Cardiothorac Surg.* 2012 Oct;42(4):e66-72. doi: 10.1093/ejcts/ezs385.
5. Endo S, Murayama F, Hasegawa T, Yamamoto S, Yamaguchi T, Sohara Y. et al. Guideline of surgical management based on diffusion of descending necrotizing mediastinitis. *Jpn J Thorac Cardiovasc Surg.* 1999 Jan;47(1):14-9. doi: 10.1007/BF03217934.
6. Freeman RK, Vallières E, Verrier ED, Karmy-Jones R, Wood DE. Descending necrotizing mediastinitis: an analysis of the effects of serial surgical debridement on patient mortality. *J Thorac Cardiovasc Surg.* 2000 Feb;119(2):260-7. doi: 10.1016/S0022-5223(00)70181-4.
7. Sugio K, Okamoto T, Maniwa Y, Toh Y, Okada M, Yamashita T. et al. Descending necrotizing mediastinitis and the proposal of a new classification. *JTCVS Open.* 2021 Aug 19;8:633-647. doi: 10.1016/j.xjon.2021.08.001.
8. Misthos P, Katsaragakis S, Kakaris S, Theodorou D, Skottis I. Descending necrotizing anterior mediastinitis: analysis of survival and surgical treatment modalities. *J Oral Maxillofac Surg.* 2007 Apr;65(4):635-9. doi: 10.1016/j.joms.2006.06.287.
9. Palma DM, Giuliano S, Cracchiolo AN, Falcone M, Ceccarelli G, Tetamo R. et al. Clinical features and outcome of patients with descending necrotizing mediastinitis: prospective analysis of 34 cases. *Infection.* 2016 Feb;44(1):77-84. doi: 10.1007/s15010-015-0838-y.
10. Taylor M, Patel H, Khwaja S, Rammohan K. Descending cervical mediastinitis: the multidisciplinary surgical approach. *Eur Arch Otorhinolaryngol.* 2019 Jul;276(7):2075-2079. doi: 10.1007/s00405-019-05471-z.
11. Sumi Y. Descending necrotizing mediastinitis: 5 years of published data in Japan. *Acute Med Surg.* 2014 Jun 26;2(1):1-12. doi: 10.1002/ams2.56.
12. Okumura T, Tetsuka N, Yamaguchi M, Suzuki T, Torii

- Y, Kawada JI. et al. A case of descending necrotizing mediastinitis in a previously healthy child. *Case Rep Pediatr.* 2021 Sep 16;2021:3159092. doi: 10.1155/2021/3159092.
13. Petitpas F, Blancal JP, Mateo J, Farhat I, Naija W, Porcher R. et al. Factors associated with the mediastinal spread of cervical necrotizing fasciitis. *Ann Thorac Surg.* 2012 Jan;93(1):234-8. doi: 10.1016/j.athoracsur.2011.09.012.
14. Kang SK, Lee S, Oh HK, Kang MW, Na MH, Yu JH. et al. Clinical features of deep neck infections and predisposing factors for mediastinal extension. *Korean J Thorac Cardiovasc Surg.* 2012 Jun;45(3):171-6. doi: 10.5090/kjtcs.2012.45.3.171.
15. De Palma A, Cantatore MG, Di Gennaro F, Signore F, Panza T, Brascia D. et al. Multidisciplinary approach in the treatment of descending necrotizing mediastinitis: twenty-year single-center experience. *Antibiotics (Basel).* 2022 May 16;11(5):664. doi: 10.3390/antibiotics11050664.
16. Wu P, Ye F, Zhang Z, Zhang L, Lin H, Ye F. et al. Descending necrotizing mediastinitis: analysis of 9 cases in our hospital. *Ear Nose Throat J.* 2021 Jun;100(5):350-353. doi: 10.1177/0145561320933964.
17. Abu-Omar Y, Kocher GJ, Bosco P, Barbero C, Waller D, Gudbjartsson T. et al. European Association for Cardio-Thoracic Surgery expert consensus statement on the prevention and management of mediastinitis. *Eur J Cardiothorac Surg.* 2017 Jan;51(1):10-29. doi: 10.1093/ejcts/ezw326.
18. Isowa N, Yamada T, Kijima T, Hasegawa K, Chihara K. Successful thoracoscopic debridement of descending necrotizing mediastinitis. *Ann Thorac Surg.* 2004 May;77(5):1834-7. doi: 10.1016/S0003-4975(03)01260-8.