

Granuloma piogénico da Cymba Concha – localização incomum de uma lesão benigna

Caso Clínico

Autores

José Pedro Carneiro

Serviço de Otorrinolaringologia do Centro Hospitalar e Universitário de Coimbra, Portugal

Hugo Barcelos Figueiredo

Serviço de Otorrinolaringologia do Centro Hospitalar e Universitário de Coimbra, Portugal

Davide Lourenço Marques

Serviço de Otorrinolaringologia do Centro Hospitalar e Universitário de Coimbra, Portugal

Rui Almeida

Serviço de Otorrinolaringologia do Centro Hospitalar e Universitário de Coimbra, Portugal

Filipa Carvalho

Serviço de Otorrinolaringologia do Centro Hospitalar e Universitário de Coimbra, Portugal

Clara Silva

Serviço de Otorrinolaringologia do Centro Hospitalar e Universitário de Coimbra, Portugal

António Miguéis

Serviço de Otorrinolaringologia do Centro Hospitalar e Universitário de Coimbra, Portugal

Jorge Miguéis

Serviço de Otorrinolaringologia do Centro Hospitalar e Universitário de Coimbra, Portugal

Correspondência:

José Pedro Carneiro
jbarros Carneiro@gmail.com

Artigo recebido a 12 de Janeiro de 2024.

Aceite para publicação a 29 de Março de 2024.

Resumo

O granuloma piogénico é uma lesão benigna da pele ou da mucosa que ocorre frequentemente na região da cabeça e pescoço.

A descrição desta lesão no pavilhão auricular ou noutras regiões do ouvido externo é muito rara, com 7 casos publicados na literatura nos últimos 20 anos. O tratamento consiste na excisão cirúrgica da lesão.

Apresentamos o caso de uma jovem de 20 anos que se apresenta com uma lesão friável do pavilhão auricular, na região da cymba concha.

Foi efetuada a excisão da mesma, sob anestesia local. Uma semana após a excisão da lesão, apresentava uma pequena crosta no local da excisão.

Seis meses após a excisão da lesão, não apresentava sinais de recidiva ou defeitos estéticos visíveis.

Palavras-chave: granuloma piogénico; pavilhão auricular

Introduction

Pyogenic granuloma (PG), more correctly known as lobular capillary hemangioma, is a benign vascular tumor lesion of the skin or mucosa, which can bleed easily after minor trauma. It occurs most frequently between 20 and 40 years of age¹. Although the sex ratio is not consensual in the literature, it is known that PGs that originate from the mucosa, are twice as common in women, and that they are associated with hormonal changes, particularly those occurring during pregnancy¹⁻³. In addition to hormonal influences, local trauma or irritation have also been identified as possible etiological factors⁴. PG occurs most frequently in the head and neck region, followed by the upper limbs, trunk, and finally the lower limbs². In the head and neck region, location in the external ear is very rare, with only 7 cases published in the

last 20 years^{1,3-8}. Clinical cases published in the literature describe the appearance of this lesion in the external auditory canal and ear pinna. It can rapidly grow and obstruct external auditory canal, leading to conductive hearing loss⁷. In one case, an association with previous location of ear piercing was described⁸. We present a clinical case of a PG in the *cymba concha* region, in a young woman with no apparent triggering factors.

Clinical case

A 20-year-old woman, with no past medical history, presented to the emergency department with a pedunculated, rounded and friable lesion in the region of the cymba

concha of the right auricle. The lesion appeared approximately 3 weeks earlier, initially as a small bump that the patient associated with the presence of a furuncle. The patient scratched the lesion, which bled and became smaller. However, it grew again, becoming larger (figure 1A) and easily bleeding, so the patient decided to seek healthcare.

The clinical history was suggestive of the presence of a PG, so an excisional biopsy was performed under local anesthesia (injection into the pedicle region of a pre-made solution of 1% lidocaine with 1:200,000 adrenaline), under microscopic visualization, followed by suture with 4-0 silk (figure 1B). Histopathological analysis confirmed the diagnosis (figure 2).

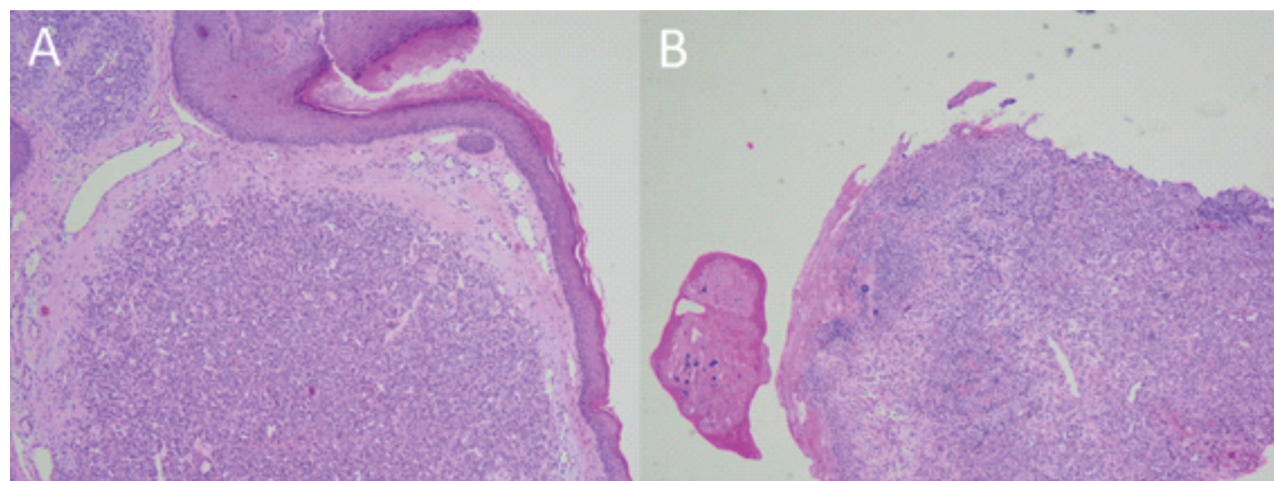
Figure 1

A – a small pedunculated, round and friable lesion on the cymba concha of the right auricle. B – an excisional biopsy was done after local anesthesia. C – an almost imperceptible scab was present at excision site 1 week later. D – no signs of recurrence and no aesthetic

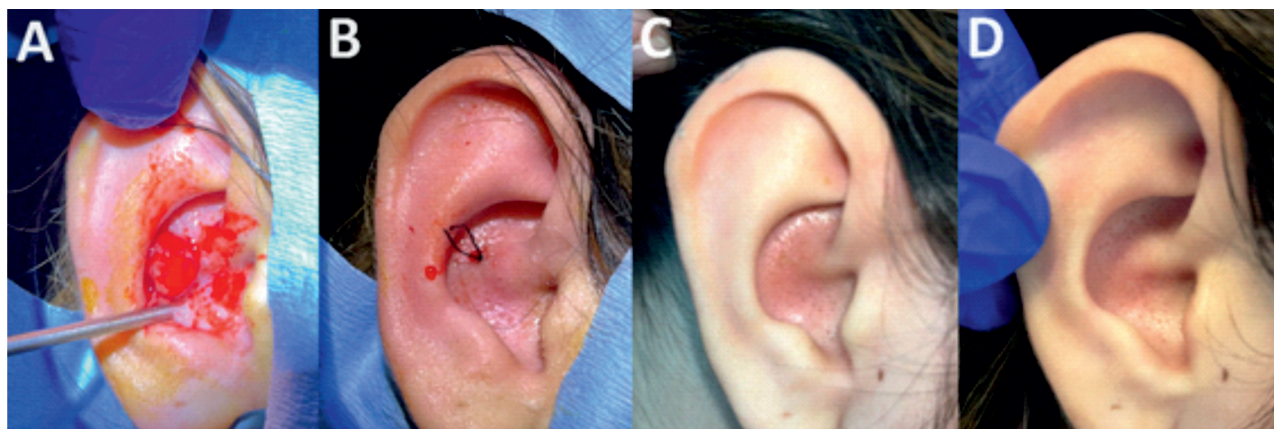

Figure 2

A – Lobular pattern proliferation of capillary-like vessels. B – Ulcerated area of the lesion



One week after excision of the lesion, there was a small scab in the excision area (Figure 1C). Six months after excision, she did not present any aesthetic changes or signs of local recurrence (Figure 1D).

Discussion

Pyogenic granuloma of the ear is a rare lesion. The most affected site that has been reported in the literature is the head and neck region, as described in the review of 408 cases published by Giblin and colleagues²; in their work, 36% of cases relate to this region, with the lips (23.2%), cheek (18%), intraoral (17.4%) and neck (13%) reflecting most cases; the ear represented only 3% of cases related to this region. Koo and colleagues also did a retrospective analysis of 155 cases and found that 30% of the lesions were located on various regions of the face; they do not describe any lesions in the ear region⁹. Although some etiological associations have been suggested, our case, like most cases described in the literature, appears to have none. Differential diagnosis includes many other lesions (such as spitz naevus, common warts, true haemangiomas, amelanotic melanoma, squamous cell carcinoma, spindle cell tumours, amongst others)², but this case demonstrates that, with a high index of suspicion, the diagnosis must be made based on an excisional.

PG is a lesion that grows rapidly, and failure to remove it from the ear region can lead to functional changes, such as conductive hearing loss due to obstruction of the external auditory canal, as well as hemorrhage and aesthetic changes. Several treatments have been proposed for the treatment of these injuries, with different success rates². The main objectives should be complete removal of the lesion and an aesthetically acceptable result. Pagliai and colleagues contacted the parents of 76 children previously treated for pyogenic granulomas with different treatments (surgical excision, cauterization, laser) and between 33 and 55% reported some subtle scarring, depending on the technique used; however, regardless of the technique used, 100% were satisfied with the cosmetic result¹⁰. Our case

shows that, depending on the location of the lesion, an excellent functional and aesthetic result can be obtained with a simple surgical procedure, under local anesthesia.

Conflict of interest

The authors declare that they have no conflict of interest regarding this article.

Data confidentiality

The authors declare that they followed their work protocols when publishing patient data.

People and animals' protection

The authors declare that the procedures followed are in accordance with the regulations established by the directors of the Committee for Clinical Research and Ethics and in accordance with the Declaration of Helsinki of the World Medical Association.

Privacy policy, informed consent and Ethics Committee Authorization

Os autores declaram que têm o consentimento por escrito para o uso de fotografias dos pacientes neste artigo.

Financing

This work did not receive any contribution, funding or scholarship.

Availability of scientific data

There are no publicly available datasets related to this work.

Bibliographic references

1. Dick DC, Elliott K, Napier S, Adair R. Pregnancy tumour of the external auditory canal: treatment in clinic. *BMJ Case Rep.* 2016 Feb 16;2016:bcr2015213673. doi: 10.1136/bcr-2015-213673.
2. Giblin AV, Clover AJ, Athanassopoulos A, Budny PG. Pyogenic granuloma - the quest for optimum treatment: audit of treatment of 408 cases. *J Plast Reconstr Aesthet Surg.* 2007;60(9):1030-5. doi: 10.1016/j.bjps.2006.10.018.
3. Song K, Lee J, Park MJ, Lee HY. A case of bilateral external auditory canal pyogenic granuloma in a pregnant woman. *J Audiol Otol.* 2018 Oct;22(4):244-247. doi: 10.7874/jao.2018.00010.
4. Huang TR, Lin YJ, Chen HC. Pyogenic granuloma of the auricle. *Ear Nose Throat J.* 2022 Nov;101(9):NP373-NP374. doi: 10.1177/0145561320968924.
5. Hsu CH, Chen HC, Wang CH. Bilateral external auditory

- canal pyogenic granuloma. *Otolaryngol Head Neck Surg.* 2008 Oct;139(4):596-7. doi: 10.1016/j.otohns.2008.06.029.
6. Magliulo G, Iannella G, Gianno F, Re M. Lobular capillary hemangioma and external auditory canal. *Otol Neurotol.* 2014 Aug;35(7):e213-4. doi: 10.1097/MAO.0000000000000377.
7. Rehman S, Loizou P, Singh PK. Obstruction of the external auditory meatus secondary to a giant pyogenic granuloma. *BMJ Case Rep.* 2015 Dec 7:2015:bcr2015211196. doi: 10.1136/bcr-2015-211196.
8. Thomas J, Sindhu BR. Pyogenic granuloma at ear piercing site: report of a case. *Indian Dermatol Online J.* 2014 Jul;5(3):347. doi: 10.4103/2229-5178.137801.
9. Koo MG, Lee SH, Han SE. Pyogenic Granuloma: A retrospective analysis of cases treated over a 10-year. *Arch Craniofac Surg.* 2017 Mar;18(1):16-20. doi: 10.7181/acfs.2017.18.1.16
10. Pagliai KA, Cohen BA. Pyogenic granuloma in children. *Pediatr Dermatol.* 2004 Jan-Feb;21(1):10-3. doi: 10.1111/j.0736-8046.2004.21102.x.