

Arytenoid bilateral subluxation following laryngeal mask airway – first case report

Caso Clínico

Autores

Tiago Caneira

Hospital CUF Descobertas, Portugal

João Subtil

Hospital CUF Descobertas, Portugal

Rita Fragoso

Hospital CUF Descobertas, Portugal

João Araújo

Hospital CUF Descobertas, Portugal

Alberto Santos

Hospital CUF Descobertas, Portugal

Carlos Macor

Hospital Beatriz Ângelo, Portugal

Correspondência:

Tiago Caneira

caneira.tiago@gmail.com

Artigo recebido a 14 de Dezembro de 2021.

Aceite para publicação a 5 de Janeiro de 2022.

Resumo

A máscara laríngea é um dispositivo prático e simples para assegurar a via aérea, raramente com complicações associadas.

Um doente do sexo masculino, 28 anos, submetido a cirurgia ortopédica sob anestesia combinada - bloqueio do plexo braquial associado a anestesia geral balanceada - sem complicações aparentes.

No recobro, o doente apresentou uma disфонia evidente, sem outras queixas associadas. A observação com videolaringoscopia revelou encerramento glótico incompleto com aparente luxação bilateral posterior das cartilagens aritnoideias. A tomografia computadorizada confirmou o diagnóstico. O doente foi tratado de forma conservadora com reabilitação vocal, com resolução completa do quadro após 4 semanas.

A máscara laríngea é atualmente uma opção na abordagem da via aérea, sendo as complicações associadas raras. Este caso ilustra o primeiro caso descrito de luxação bilateral das aritnoideias como complicação de intubação com máscara laríngea que foi gerida de forma conservadora.

Palavras-chave: Máscara laríngea, Luxação traumática, Complicação anestésica, Caso clínico.

Introduction

Laryngeal mask intubation is a convenient alternative to endotracheal intubation to establish airways and was introduced in the 80-decade of the last century¹. It allows rapid intubation, dismissing laryngoscopy for glottis visualization, and is therefore a formidable tool in emergency settings¹.

Relevant complications are infrequent and include aspiration, pharyngeal rupture, pneumomediastinum, mediastinitis and arytenoid dislocation². Other more common, but mild and short-lasting adverse effects include postoperative sore throat, dysphagia, pain on swallowing, hoarseness, laryngeal spasm, bronchospasm, vocal cords pathology or nerve palsy (laryngeal recurrent nerve, lingual nerve or hypoglossal nerve)^{2,3}. Usually, cuff pressure is the mechanism behind the lesion^{2,4}.

Arytenoid subluxation/dislocation is caused by a disruption of the cricoarytenoid joint with hoarseness being the most common symptom. It can be classified as anterior or posterior. It most commonly occurs as a result of intubation trauma but it can also be caused by external neck trauma. We present the first case of bilateral arytenoid dislocation after laryngeal mask intubation and its management.

Case Report

A 28-year-old male, 185 cm height and 75 Kg weight, ASA I, with no airway problems expected, was submitted under general anesthesia to open osteosynthesis of a left humerus fracture after a bike accident. Anesthesia protocol was a combined interscalene brachial plexus block with

balanced general anesthesia with laryngeal mask airway (LMA) 4 ½ air-Qsp® (shown in Fig. 1).

The block was performed under ultrasound guidance while awoken. 15ml of ropivacaine 0,5% was uneventfully injected. Endovenous induction with fentanyl and propofol was conducted. LMA was easily inserted at first attempt. Anesthesia was maintained with sevoflurane, mixed in oxygen enriched air. Ventilation was uneventful, always less than 15 cm H2O, with no degradation in vital signs. The procedure took 3 hours in a sitting position.

After awaking, severe hoarseness with weak, hoarse and breathy voice (GRBAS scale – Grade, Roughness, Breathiness, Aesthenia, Strain - 2,2,3,0,0), was observed in the post-anesthesia care unit (PACU), without dyspnea, stridor, cough, pain or dysphagia. Vital signs were normal. The patient was discharged the next day. Since hoarseness was still present on reobservation after 7 days, an ENT consultation was scheduled. There, videolaryngoscopy and stroboscopy observation showed incomplete glottic closure with bilateral and symmetrical limitation of vocal fold mobility, with apparent bilateral posterior dislocation of arytenoid cartilages (shown in Fig. 2 with QR code for the video). The diagnosis was confirmed with computerized tomography (CT) showing

Figura 1
Laryngeal mask airway (LMA) 4 ½ air-Qsp®

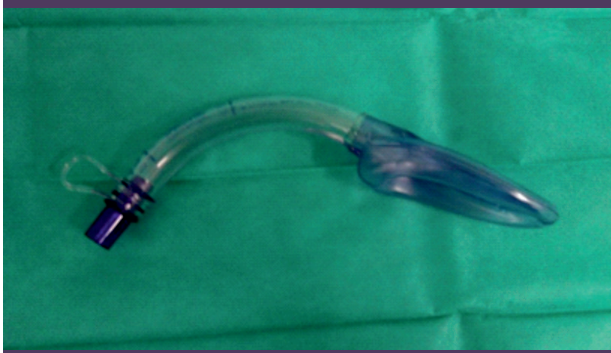

Figura 2
Videolaryngoscopy with apparent bilateral posterior dislocation of arytenoid cartilages. QR code for the video

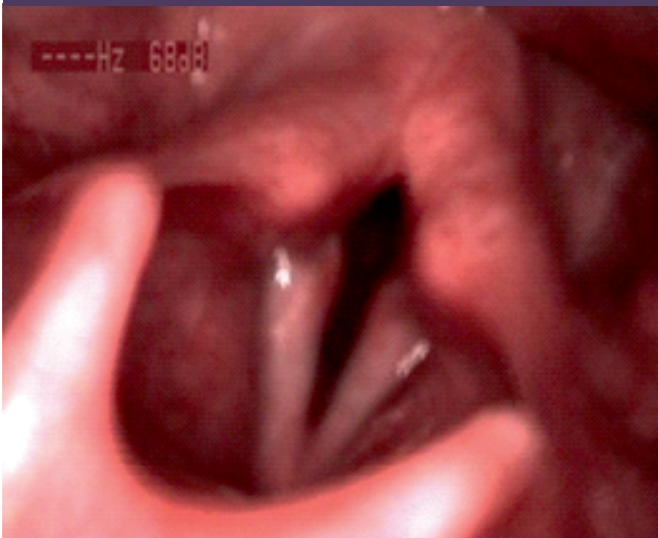
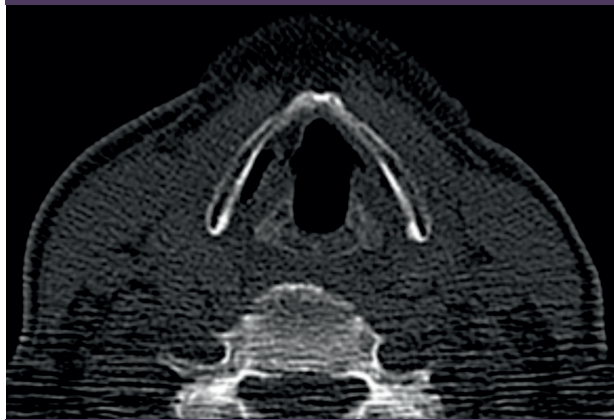


Figura 3
Cervical CT (axial cut) - bilateral posteriorly luxated arytenoid cartilages

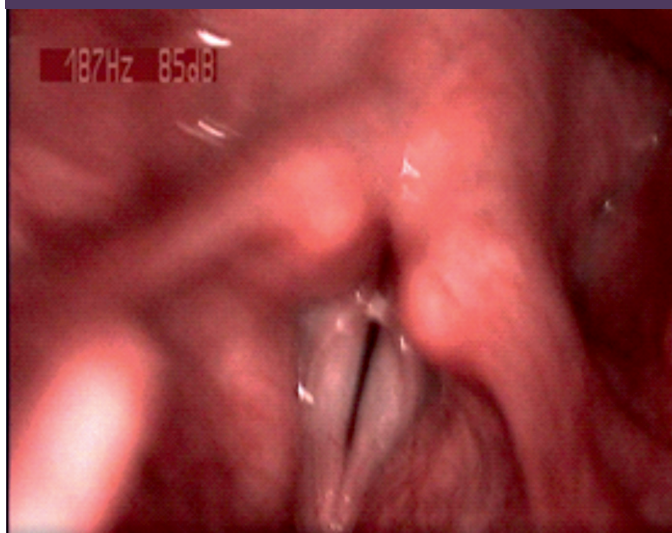

bilateral posteriorly, laterally and inferiorly luxated arytenoid cartilages, and rotated medially in resting (abduction) position (shown in Fig. 3).

This arytenoid dislocation was presumably caused by inadvertent malposition of the LMA, possibly with the tip folded in the hypopharynx, as other possible causes, as cuff overpressure, were eliminated.

After diagnosis, he was referred to speech therapy. The patient recovered rapidly and was asymptomatic after a month of treatment. Videolaryngoscopy at 3 months was normal and he was discharged from ENT

Figura 4
Videolaryngoscopy and stroboscopy after total recuperation. QR code for the video



consultation (figure 4 – QR code for video: videolaryngoscopy and stroboscopy after total recuperation).

Discussion

Arytenoid dislocation is rare and poorly documented⁵. It's caused by external neck trauma or as an iatrogenic injury during/after intubation/extubation.

It can be classified as anterior or posterior⁵. Regarding the topic of iatrogenic injury, the former usually caused by injury during extubation and the latter from injury due to the tip of the laryngoscope during intubation. Most published literature is related to endotracheal intubation (only 57 cases

published)⁵ and its mechanisms are well understood in this setting. However, since using LMA is recent, and arytenoid dislocation is rare, we still do not fully understand this complication related to this method. Even its incidence with LMA is still unknown, and probably underreported, as for endotracheal intubation⁵. We found two published cases of unilateral arytenoid luxation after LMA^{6,7}. To our knowledge, no bilateral arytenoid luxation has been described.

There are several theories to explain the postintubation injury mechanism. Rosenberg⁶ presumes to be related to direct contact with arytenoids during insertion with inflated cuff, overpressing the arytenoids, leading

to dislocation. Also, device rotation during placement, with folding into the larynx vestibule, pressing the arytenoids from above might cause posterior and inferior dislocation. Unlike for endotracheal intubation, where we find mostly unilateral dislocations⁶, here we presume the symmetrical trauma to be the rule, and therefore we should find, more often than not, bilateral dislocations. This symmetry, in turn, makes endoscopic diagnosis more difficult and may be a reason for the scarcity of published cases.

We suggest that the risk of arytenoid dislocation should be integrated in the informed consent given by Anesthesiologists and any difficulty during intubation should be communicated to the ENT surgeon for further evaluation.

The most common symptom of this complication is hoarseness. A clear diagnosis is always difficult, because endoscopic aspects overlap with postintubation oedema, and paralysis from nerve trauma, and furthermore, the direction of the dislocation is also difficult to determine, because the superior portion of the cartilage may not follow the body dislocation⁸. We believe, stroboscopy in the eyes of an experienced otolaryngologist makes diagnosis easier. Most of the times, especially in younger patients, laryngeal cartilages are not mineralized, and are not radio-opaque, which makes imaging studies inconclusive⁵. A nondiagnostic CT scan does not exclude the diagnosis⁵. In our patient, CT scan was suggestive of posterior dislocation, with a reduced cricoarytenoid joint space.

An electromyography of the laryngeal musculature could have been helpful in confirming the normal innervation of the larynx (excluding nerve paralysis for example), especially if there was an uncertainty about the diagnosis.

Early diagnosis allows early treatment, which is preferred and presumed to bring better prognosis. Several treatment modalities have been published, from voice therapy, closed reduction, open approaches and botulinum toxin injection⁵. The crico-arytenoid joint is an

arthrodial joint that allows gliding, rocking and rotation movements⁹ and is moved by several intrinsic laryngeal muscles. In our mind, the fact that we find so few cases in the literature is due to a good prognosis and to a high rate of self-resolution — the intrinsic laryngeal muscle ensemble helps to reposition the subluxated cartilages, and therefore voice therapy is helpful. We also consider that cartilage direct manipulation may lead to further dislocation or dislocation on the opposite direction, mostly because correct directional diagnosis is so difficult⁸. Additionally, it may also add capsule stretching and even mucosal or cartilage injury, making prognosis worse. So, an early intervention with voice therapy may solve at least some of these rare cases. For those that are not showing any signs of recovering, closed reduction may be attempted. This delay in close reduction is acceptable^{10,11} and it showed better results when performed until 10 weeks after the injury⁵.

Closed reduction is performed under local anesthesia with the patient sedated⁵. Normally, a posterior dislocation can be achieved using a straight-bladed laryngoscope to lift the arytenoid anterosuperiorly as described elsewhere⁵. External cricoid pressure may be helpful. Anterior dislocation is reduced using an Holinger laryngoscope⁵ (used in laryngeal microsurgery).

Some cases will not be successful and eventually evolve to chronicity and may or may not need adjuvant phonosurgical procedures, such as vocal cord injection or laryngeal framework surgery (Thyroplasty and arytenoid abduction/adduction).

Open surgical reductions (via laringofissure for example)⁵ are normally used in cases of external trauma where other lesions are normally present.

Fortunately, our patient was offered voice therapy three sessions per week, with success in less than a month

Conclusion

Hoarseness is usually a frequent and benign sign after airway intubation. LMA is a very

convenient tool, especially in emergency settings, and relevant complications remain rare. This singular case illustrates the first published case of bilateral arytenoid dislocation after LMA and was treated with voice therapy. It is important to properly follow-up patients after LMA, so we don't miss rare but potentially treatable complications.

Agradecimentos

Sem agradecimentos.

Conflito de Interesses

Os autores declaram que não têm qualquer conflito de interesse relativo a este artigo.

Confidencialidade dos dados

Os autores declaram que seguiram os protocolos do seu trabalho na publicação dos dados de pacientes.

Proteção de pessoas e animais

Os autores declaram que os procedimentos seguidos estão de acordo com os regulamentos estabelecidos pelos diretores da Comissão para Investigação Clínica e Ética e de acordo com a Declaração de Helsínquia da Associação Médica Mundial.

Política de privacidade, consentimento informado e Autorização do Comité de Ética

Os autores declaram que têm o consentimento para o uso de fotografias e vídeos dos pacientes neste artigo.

Financiamento

Este trabalho não recebeu qualquer contribuição, financiamento ou bolsa de estudos.

Disponibilidade dos Dados científicos

Não existem conjuntos de dados disponíveis publicamente relacionados com este trabalho.

Referências bibliográficas

1. Pollack CV. The laryngeal mask airway: a comprehensive review for the Emergency Physician. *J Emerg Med*. 2001 Jan;20(1):53-66. doi: 10.1016/s0736-4679(00)00273-0.
2. Michalek P, Donaldson W, Vobrubova E, Hakl M. Complications associated with the use of supraglottic airway devices in perioperative medicine. *Biomed Res Int*.

2015;2015:746560. doi: 10.1155/2015/746560.

3. Hensel M, Güldenpfennig T, Schmidt A, Krumm M. Continuous cuff pressure measurement during laryngeal mask anaesthesia: an obligatory measure to avoid postoperative complications. *Anaesthesist*. 2016 May;65(5):346-52. doi: 10.1007/s00101-016-0160-9

4. Shin HW, Yoo HN, Bae GE, Chang JC, Park M2, You HS. et al. Comparison of oropharyngeal leak pressure and clinical performance of LMA ProSeal™ and i-gel® in adults: Meta-analysis and systematic review. *J Int Med Res*. 2016 Jun;44(3):405-18. doi: 10.1177/0300060515607386.

5. Sataloff RT, Bough ID, Spiegel JR. Arytenoid dislocation: diagnosis and treatment. *Laryngoscope*. 1994 Nov;104(1 Pt 1):1353-61. doi: 10.1288/00005537-199411000-00007.

6. Rosenberg MK, Rontal E, Rontal M, Lebenbom-Mansour M. Arytenoid cartilage dislocation caused by a laryngeal mask airway treated with chemical splinting. *Anesth Analg*. 1996 Dec;83(6):1335-6. doi: 10.1097/00000539-199612000-00037.

7. Cros AM, Pitti R, Conil C, Giraud D, Verhulst J. Severe dysphonia after use of a laryngeal mask airway. *Anesthesiology*. 1997 Feb;86(2):498-500. doi: 10.1097/00000542-199702000-00027.

8. Close LG, Merkel M, Watson B, Schaefer SD. Cricoarytenoid subluxation, computed tomography, and electromyography findings. *Head Neck Surg*. Jul-Aug 1987;9(6):341-8. doi: 10.1002/hed.2890090607.

9. Maue WM, Dickson DR. Cartilages and ligaments of the adult human larynx. *Arch Otolaryngol*. 1971 Nov;94(5):432-9. doi: 10.1001/archotol.1971.00770070678008.

10. Lee DH, Yoon TM, Lee JK, Lim SC. Treatment outcomes of closed reduction of arytenoid dislocation. *Acta Otolaryngol*. 2013 May;133(5):518-22. doi: 10.3109/00016489.2012.758387.

11. Lou Z, Lin Z. The appropriate time for closed reduction using local anesthesia in arytenoid dislocation caused by intubation: a clinical research. *Acta Otolaryngol*. 2017 Mar;137(3):331-336. doi: 10.1080/00016489.2016.1230276.