

Pott's puffy tumor and orbital abscess - Unusual cause

Caso Clínico

Autores

Liliana Filipa Invecio da Costa

Hospital Universitário Arnau de Vilanova de Lleida,
Spain

Laura Acevedo Ortiz

Hospital Universitário Arnau de Vilanova de Lleida,
Spain

Antonio Ruiz Giner

Hospital Universitário Arnau de Vilanova de Lleida,
Spain

Xavier Francisco Galindo Ortego

Hospital Universitário Arnau de Vilanova de Lleida,
Spain

Correspondência:

Liliana Filipa Invecio da Costa
liliana.invecion@gmail.com

Artigo recebido a 13 de Julho de 2023.
Aceite para publicação a 22 de Setembro de 2023.

Resumo

Introduction: Pott's Puffy tumor is a subperiosteal abscess that typically arises from frontal osteomyelitis. It can also originate from sinus tumors, with squamous cell carcinoma being the most frequent histological type.

Clinical case: A 72-year-old male presented with orbital and frontal cellulitis. Subsequent CT and MRI scans revealed the presence of a mass in both frontal sinuses, which led to bone erosion and the formation of an abscess in the frontal region, known as Pott's Puffy tumor. The abscess was drained, and a biopsy confirmed a monoclonal plasmablastic lymphoma. Following the completion of an intravenous antibiotic regimen, the patient underwent chemotherapy, which resulted in the remission of the tumor.

Discussion: Plasmablastic lymphoma is an unusually aggressive subtype of large B-cell non-Hodgkin's lymphoma that primarily affects mucosal membranes, with a predilection for the oral cavity. Due to its low incidence, there is currently no established treatment approach for this condition.

Keywords: Orbital Disease, Plasmablastic Lymphoma, Pott Puffy Tumor, Frontal Sinusitis, Paranasal Sinus Neoplasms

Introduction

Pott's puffy tumor is a subperiosteal abscess that forms as a result of frontal osteomyelitis. It occurs in less than 20% of sinusitis cases and is more commonly seen in young and immunocompromised patients.

While untreated frontal sinusitis is the primary cause, it is important to note that Pott's puffy tumors can also develop from sinus tumors¹. Sinus tumors account for approximately 3-5% of head and neck tumors and are more prevalent in males over the age of 50. The nasal cavity is the most frequently affected site, followed by the maxillary sinus, ethmoidal sinus, sphenoid sinus, and finally the frontal sinus.²

Case report

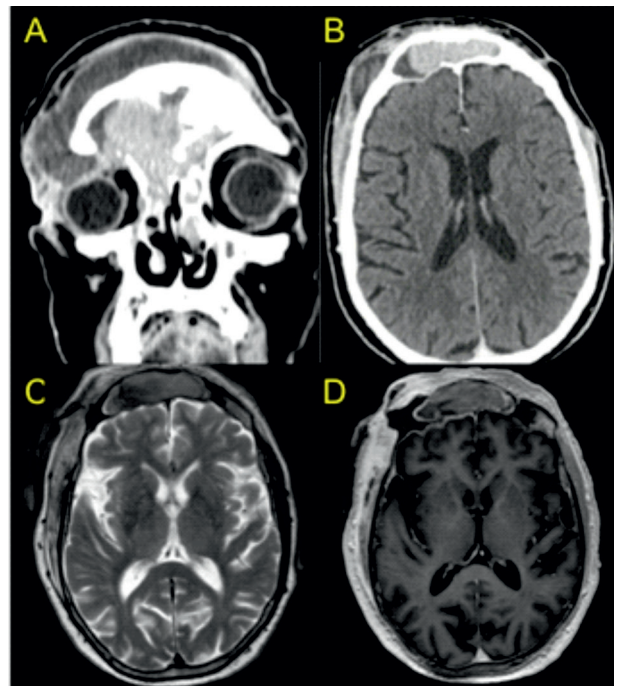
A 72-year-old patient with a medical history of hypertension and diabetes, managed with oral anti-diabetic medication, presented to the emergency room with frontal and periorbital cellulitis. The patient did not exhibit signs of fever, headache, or nasal congestion. On physical examination, palpebral edema was observed, restricting eye opening without affecting eye movement, visual acuity, or color perception (Fig. 1). Nasofibroscopy revealed bilateral grade I nasal polyposis, although no purulent discharge was present.

The case was diagnosed as complicated sinusitis. A CT scan showed a Pott's puffy tumor, characterized by a subperiosteal abscess in the frontal region. Additionally, a bilateral frontal sinus mass with soft tissue density was detected, leading to lysis of the anterior wall with externalization of the tumor, lysis of the right orbital roof with intraorbital collection, and lysis of the posterior wall without intracranial involvement. Further evaluation through MRI revealed the presence of material within the frontal sinus, displaying high signal on T2, low signal on T1, and homogeneous contrast uptake, suggesting several possible differential diagnoses, including infected mucocele, neoplastic processes (lymphoma or metastases), and invasive fungal sinusitis (Fig. 2).

Following drainage of the abscess, a biopsy of the lesion was performed. The procedure involved an incision at the upper palpebral fold for drainage of the subcutaneous abscess, followed by entry via the superior

Figure 2

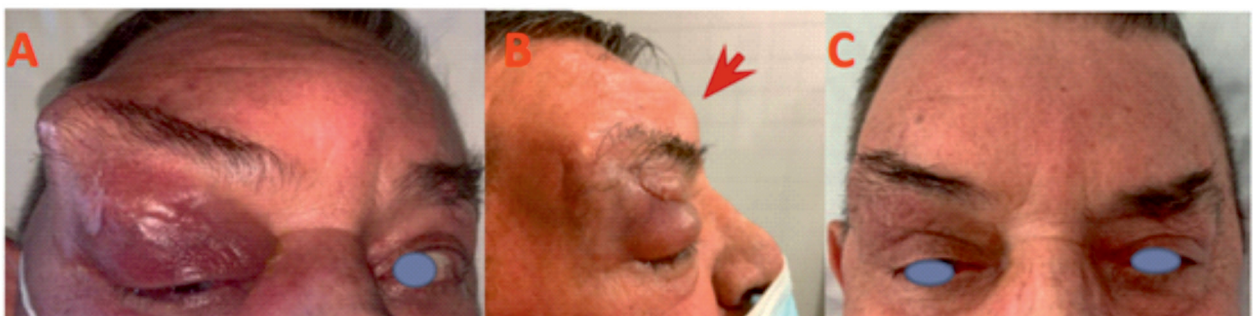(A) Coronal view and (B) Axial view of the CT scan, displaying the Pott's puffy tumor and orbital abscess associated with a mass that occupied both frontal sinuses. (C) Axial T2 MRI, with a strong T2 signal. (D) Axial T1 MRI, displaying a low T1 signal and homogeneous intravenous contrast uptake, revealing a lesion consistent with a lymphoma.



orbital rim for drainage of the orbital abscess. Finally, endoscopic access to the frontal sinus was utilized for biopsy of the mass. During endonasal inspection, small polyps were observed and biopsied as well, although no purulent discharge was observed. Corticosteroids were prescribed for one week, accompanied by a four-week course of broad-spectrum antibiotics. Cultures of the purulent exudate yielded negative results.

Figure 1

(A) Frontal view at the time of diagnosis. (B) Lateral view at the time of diagnosis. (C) Frontal view after treatment.



The patient showed satisfactory postoperative progress, with improvement in analytical parameters. A follow-up CT scan revealed complete resolution of the abscess but significant extension of the tumor into the periorbital region and externalization. Initially, periorbital edema decreased, but it subsequently increased one week later, coinciding with the tapering of corticosteroids. The biopsy confirmed the presence of a monoclonal plasmablastic lymphoma, identifiable through lambda light chain immunohistochemical staining for CD79a, CD138, and Mum1, which are specific markers for this type of lymphoma (see Image 3). Given the lymphoproliferative nature of the lesion, a PET scan was performed, which indicated that the primary lesion was the only metabolically active area.

After managing the infection, the patient's clinical condition significantly improved, and a six-cycle chemotherapeutic regimen with Bortezomib-Etoposide Phosphate, Prednisone, and Vincristine Sulfate (Bort-EPOCH) was initiated. Physical examination and imaging scans demonstrated remission of the frontal tumor. With two years of follow-up involving CT scans and PET scans, the patient remains asymptomatic.

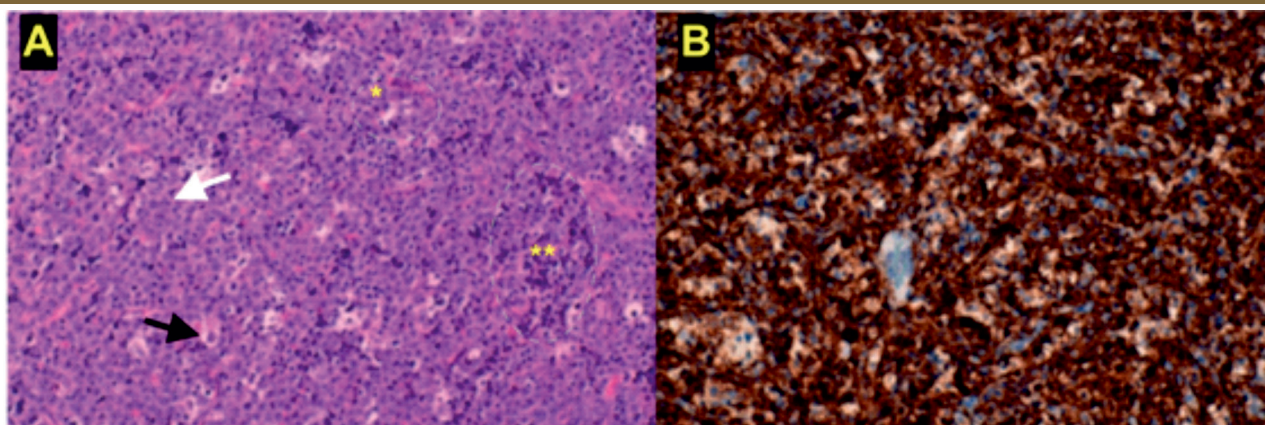
Discussion

During the investigation of sinusitis complications, conducting a CT scan or MRI is crucial for assessing the severity of complications, identifying any associated tumors, and guiding the biopsy procedure, which is essential for both diagnosis and treatment. It is worth noting that squamous cell carcinoma is the most commonly observed histology in frontal sinus tumors, whereas primary lymphomas of the frontal sinus are infrequent. In the sinonasal area, non-Hodgkin's lymphomas and plasmacytomas are the most prevalent hematolymphoid tumors. However, their occurrence in the frontal sinus is less than 1% of cases².

Plasmablastic lymphoma is a highly aggressive and rare subtype of large B-cell non-Hodgkin's lymphoma. It is frequently seen in immunocompromised individuals, including those with conditions such as HIV/AIDS, prolonged corticosteroid therapy, solid organ transplant recipients, or advanced age. This type of lymphoma tends to affect mucous membranes and shows a preference for the oral cavity and paranasal area.³⁻⁴ Due to its limited prevalence, there is currently no established treatment protocol for plasmablastic lymphoma. Various therapeutic modalities have been suggested in the literature, including chemotherapy with R-CHOP or similar regimens, chemotherapy combined

Figure 3

(A) Eosin-hematoxylin stain at 20x magnification showing the presence of plasmablasts (black arrow), centroblasts (white arrow), an angiodestructive growth pattern (*), as well as numerous mitotic and apoptosis figures (**). (B) Immunohistochemical stain at 40x magnification demonstrating a positive stain for CD138.



with radiotherapy, or a combination of chemotherapy, radiotherapy, and surgical excision of the tumor lesion. There are no specific hematological markers for follow-up. The 5-year survival rate for malignant lesions in the frontal sinus is approximately 35%. However, plasmablastic lymphomas have a poor prognosis regardless of treatment, with a survival rate ranging from 1 to 24 months and an average mortality rate of 6 months. In the presented case, the patient remains asymptomatic and in complete remission two years after completing treatment⁵⁻⁶.

Conclusion

While tumors are an uncommon underlying cause of Pott's puffy tumors, they should be considered as part of the diagnostic process. It is crucial to document cases of plasmablastic lymphoma, given its low prevalence, to expand treatment possibilities, particularly in instances where there has been a favorable response, as seen in our case.

Conflito de Interesses

Os autores declaram que não têm qualquer conflito de interesse relativo a este artigo.

Confidencialidade dos dados

Os autores declaram que seguiram os protocolos do seu trabalho na publicação dos dados de pacientes.

Proteção de pessoas e animais

Os autores declaram que os procedimentos seguidos estão de acordo com os regulamentos estabelecidos pelos diretores da Comissão para Investigação Clínica e Ética e de acordo com a Declaração de Helsínquia da Associação Médica Mundial.

Política de privacidade, consentimento informado e Autorização do Comitê de Ética

Os autores declaram que têm o consentimento por escrito para o uso de fotografias dos pacientes neste artigo.

Financiamento

Este trabalho não recebeu qualquer contribuição, financiamento ou bolsa de estudos.

References

1. Sandoval JI, De Jesus O. Pott Puffy Tumor. 2022 Aug 29. In: StatPearls [Internet]. Treasure Island (FL): StatPearls Publishing; 2022 Jan. Available from: <https://www.ncbi.nlm.nih.gov/books/NBK560789/>.
2. Turner JH, Reh DD. Incidence and survival in patients with sinonasal cancer: a historical analysis of population-based data. *Head Neck*. 2012 Jun;34(6):877-85. doi: 10.1002/hed.21830.
3. Youlden DR, Cramb SM, Peters S, Porceddu SV, Moller H, Fritschi L. et al. International comparisons of the incidence and mortality of sinonasal cancer. *Cancer Epidemiol*. 2013 Dec;37(6):770-9. doi: 10.1016/j.canep.2013.09.014.
4. Alvarez E, Gunther M, Hernández P, Misad C, Fernandez MA, Donoso-Hofer F. Revisión sistemática del linfoma plasmablasto intraoral en paciente con virus de la inmunodeficiencia humana. A propósito de un caso. *Rev Esp Cirug Oral y Maxilofacial*. 2018. Apr-Jun; 40(2): 78-83. doi: 10.1016/j.maxilo.2017.04.005.
5. Lopez F, Grau J.J, Medina AJ, Alobid I. Consenso español para el tratamiento de los tumores nasosinusales. *Acta Otorrinolaringol Esp*. 2017 Jul-Aug;68(4):226-234. doi: 10.1016/j.otorri.2016.07.001.
6. Albarrán B, Caballero D, Cabezudo M, Cabo de E, Cidoncha B, Díaz FJ et al. Guía de Linfomas. [Internet]. Madrid: Asociación de Hematología y Hemoterapia Castellano-Leonesa; 2017; 138 p. Available from: <https://www.sehh.es/publicaciones/guias-y-documentos/122408-guia-de-linfomas>.