

Facial nerve schwannoma – a rare cause of peripheral facial paralysis: clinical case and literature review

Clinical Case

Authors

Pedro Marques Gomes

Unidade Local de Saúde de Matosinhos – Hospital Pedro Hispano, Portugal

Rita Rodrigues

Unidade Local de Saúde de Matosinhos – Hospital Pedro Hispano, Portugal

André Carção

Unidade Local de Saúde de Matosinhos – Hospital Pedro Hispano, Portugal

Fátima Hierro

Unidade Local de Saúde de Matosinhos – Hospital Pedro Hispano, Portugal

Nuno Oliveira

Unidade Local de Saúde de Matosinhos – Hospital Pedro Hispano, Portugal

Delfim Duarte

Unidade Local de Saúde de Matosinhos – Hospital Pedro Hispano, Portugal

Paula Azevedo

Unidade Local de Saúde de Matosinhos – Hospital Pedro Hispano, Portugal

Correspondence:

Pedro Marques Gomes
pedrommarquesgomes@hotmail.com

Article received on July 13, 2023.

Accepted for publication on October 11, 2023.

Abstract

Facial nerve schwannoma is a benign neoplasm originating from the Schwann cells of the facial nerve. It represents approximately 5% of facial paralysis cases and should be included in the differential diagnosis of peripheral facial paralysis. This neoplasm most frequently affects the tympanic and mastoid segments of the facial nerve. Therapeutic options include surgery, stereotactic radiosurgery or 'wait and scan'. We describe the case of a patient with an acute peripheral facial palsy, otalgia and left conduction hearing loss, that was interpreted as an acute otitis media complicated with facial paralysis based on the history, physical examination and imaging findings. Due to persistence the patient was submitted to an exploratory tympanomastoidectomy which confirmed the diagnosis of facial nerve schwannoma. During the procedure, a subtotal resection of the lesion was performed, which resulted in postoperative clinical and audiological improvement. After subtotal resection, we opted for regular observation and imaging evaluation of the tumor residue. Keywords: Schwannoma, Facial nerve, Peripheral facial paralysis

Introduction

Peripheral facial paralysis (PFP) may be idiopathic (known as primary or Bell's palsy) or secondary to an identifiable cause. Idiopathic PFP is more common and is a diagnosis of exclusion. Only about one-fourth of the cases have a secondary etiology. The most prevalent causes of PFP include viral infections (such as herpes simplex, Epstein-Barr, cytomegalovirus), trauma (e.g., fracture of the temporal bone), iatrogenic surgical complications, local infections, and tumors¹. In an acute presentation, the differentiation between infectious etiology and cancer may be difficult if it is solely based

on clinical history, objective examination, and computed tomography². Facial nerve schwannoma (FNS) is the most common facial nerve tumor, accounting for 5% of the cases of facial paralysis³. In FNS, PFP can be sudden, intermittent, or progressive. In addition, it causes hypoacusis (conduction or sensorineural) in around 50% of the cases. Other possible symptoms include otalgia and vertigo. This tumor most often affects the tympanic and mastoid segments of the facial nerve⁴. In this report, we present a patient with an initial presentation of PFP, hypoacusis, and otalgia that mimicked acute otitis media complicated by PFP. He was found to have a middle ear FNS intraoperatively, which was subtotally resected with subsequent improvement in the facial function and auditory thresholds.

Clinical Case

A 49-year-old Caucasian man, with no relevant clinical history, came to the otorhinolaryngology (ORL) emergency department (ED) of Hospital Pedro Hispano (HPH) with left-sided facial paresis, preceded by intense otalgia and ipsilateral hypoacusis that had progressed for two days, with no

other associated complaints such as fever or otorrhea. On objective examination he showed left-sided facial paresis, graded IV in the House-Brackmann (HB) scale. Left otoscopy showed opacification and hyperemia of the entire tympanic membrane, with no tympanic bulging or evidence of vesicular lesions in the external auditory canal and concha or other alterations. Accumetry showed a negative Rinne test on the left side, with the Weber test lateralizing to the left side.

An audiological study conducted in the ED showed left conductive hearing loss at extreme frequencies, from severe to profound above 4000 Hz (Fig. 1).

In view of the suspicion of non-suppurative acute otitis media complicated by PFP, left myringotomy was performed in the ED and spontaneous drainage of seromucous content was observed.

After the procedure, computed tomography (CT) of the ears (Fig. 2) was performed in the ED, which showed a mass filling the left mastoid and tympanic cavity that involved the ossicular chain but did not cause erosion. The fallopian canal demonstrated no obvious changes.

Figure 1

Tone audiograms and vocal thresholds of the patient, both performed by the same audiologist in the same audiology laboratory. SRT, speech reception threshold.

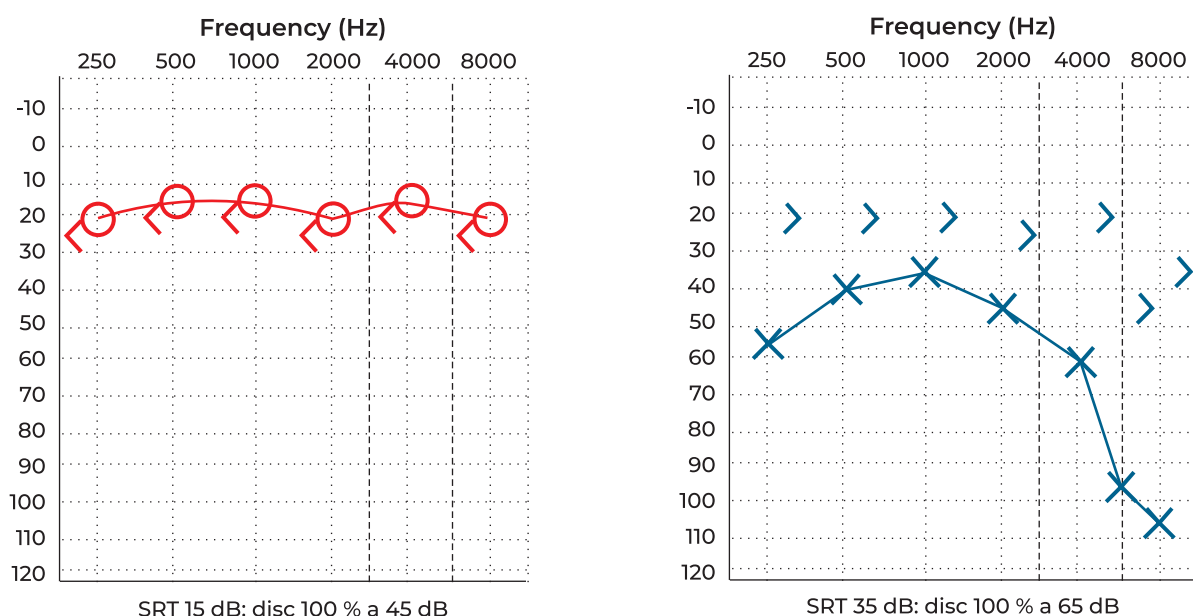
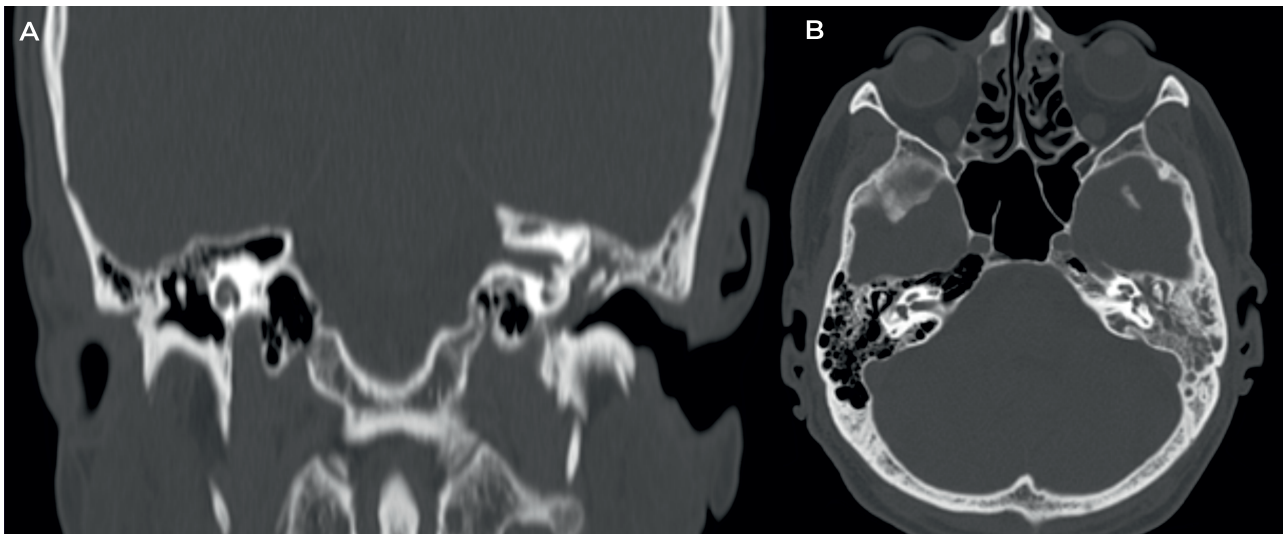


Figure 2

Computed tomography (CT) of the ears, A – Coronal plane, B – Axial plane: filling of the left mastoid and tympanic cavity that involved the ossicular chain but did not cause erosion.



The patient was discharged from the ED on oral antibiotic and corticosteroid therapy and topical ofloxacin and dexamethasone for the left ear. He was also instructed to cover the left eye with an eye patch during the night and apply artificial tears daily.

The patient was reassessed one week after the initial presentation. He showed no signs of clinical improvement, with persistent left otalgia and no improvement in the facial paresis (grade IV HB). Otoscopy revealed granulation tissue coming out from the myringotomy incision. Because there was no improvement with myringotomy combined with medical treatment, the patient was admitted for exploratory tympanomastoidectomy (Fig. 3). The patient underwent surgery one week after the initial presentation under general anesthesia with ototracheal intubation. A retroauricular approach was used. It was observed intraoperatively that the attic, *aditus ad antrum*, and mastoid antrum were filled with soft, non-pedunculated neof ormation, and little surrounding granulation. The tissue was removed from the mastoid antrum and the region lateral to the ossicular chain (which was intact and mobile), adjacent to the tympanic membrane. A sample of the newly formed tissue (Fig. 3) surrounding the

horizontal portion of the facial nerve was sent for anatomopathological analysis.

After the procedure, the patient's PFP improved from grade IV to grade III HB (Fig. 4), as did the auditory thresholds. (Fig. 5) The histological analysis of the surgical specimen indicated FNS. Immunocytochemistry showed strong and diffuse S100 positivity and negativity for CD34 and EMA. Postoperative magnetic resonance imaging (MRI) of the ear showed areas of residual linear enhancement in the region of the horizontal segment of the left facial nerve and mastoid portion, compatible with FNS (Fig. 6).

Given the clinical improvement in both the facial and hearing functions, the decision was made to undertake watchful waiting with regular observation and imaging assessment (MRI) of the residual tumor (every six months during the first year).

One year later, the patient's left middle ear was aird; there were no hearing complaints and the left PFP remained stable (grade III HB). MRI did not show growth of the lesion.

Figure 3
A – Exploratory tympanomastoidectomy. B – Surgical specimen

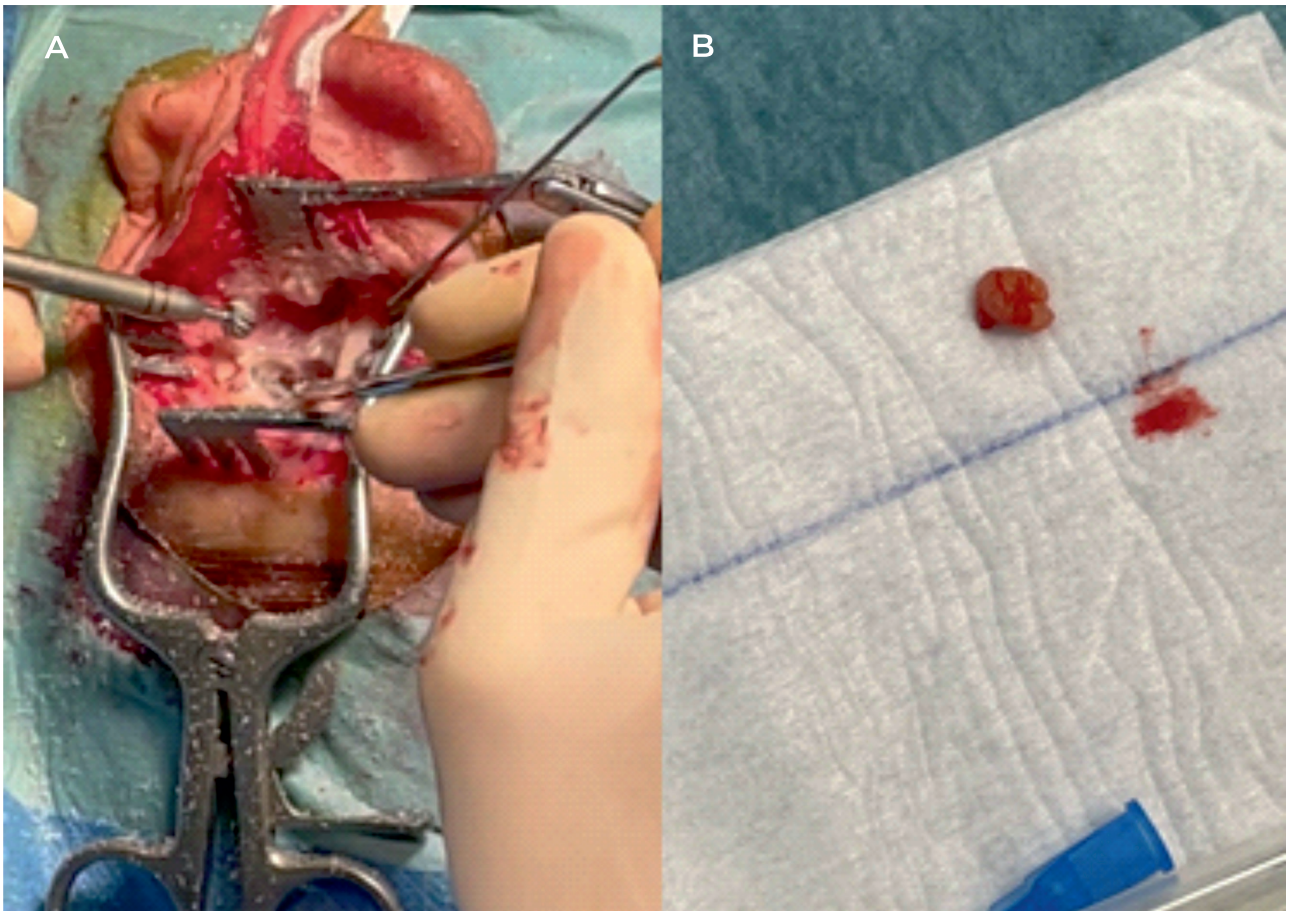
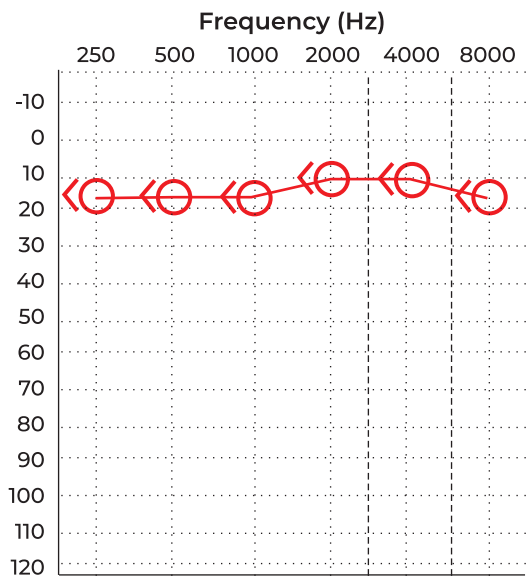


Figure 4
Postoperative grade III HB left paresis

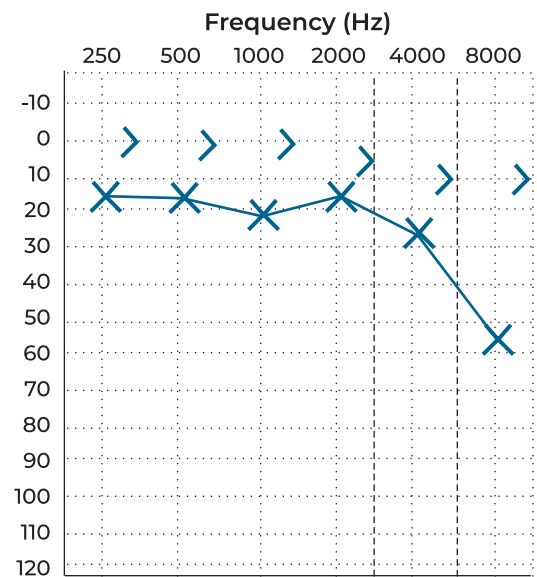


Figure 5

Postoperative tone audiograms and vocal thresholds, both performed by the same audiologist in the same audiology laboratory. SRT, speech reception threshold.



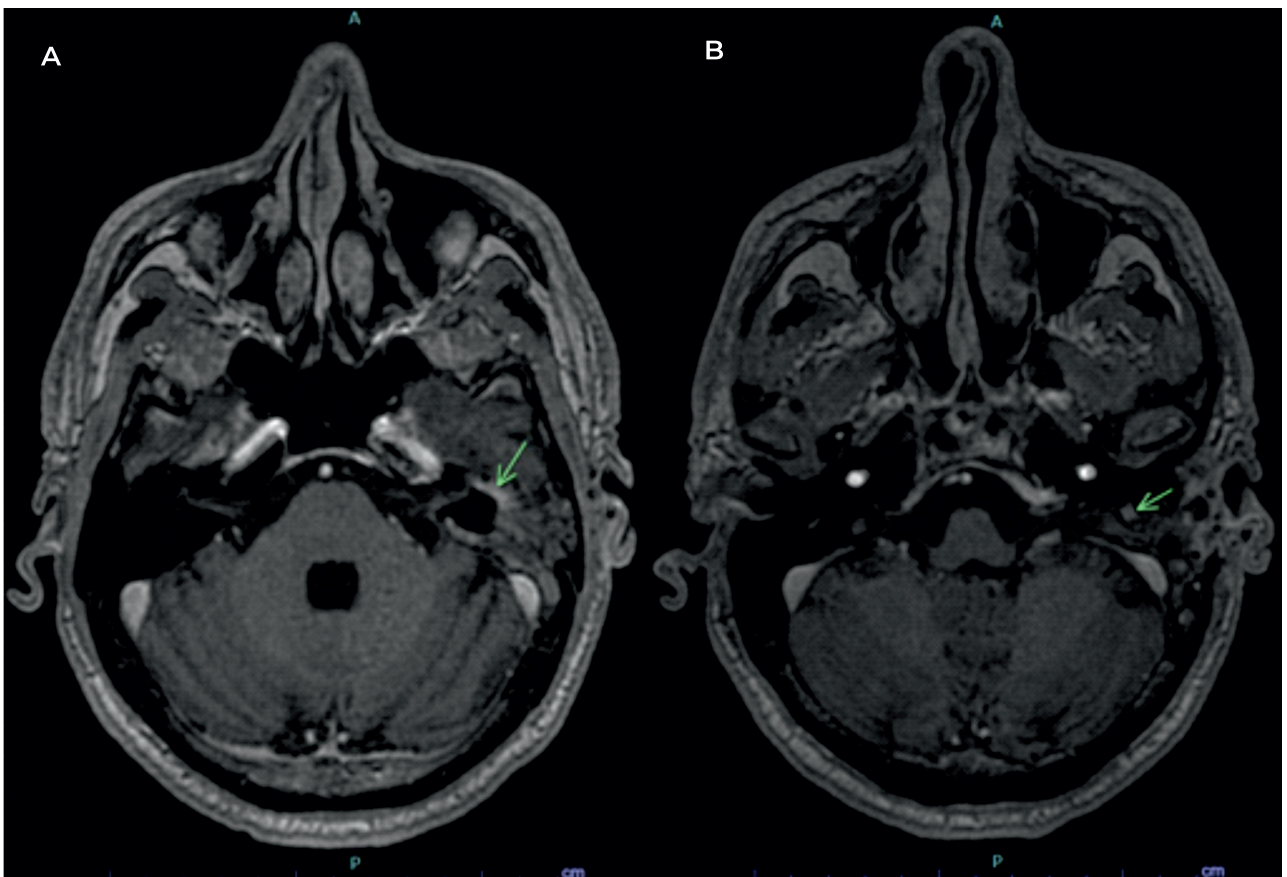
SRT 10 dB: disc 100 % a 40 dB



SRT 10 dB: disc 100 % a 40 dB

Figure 6

Magnetic resonance imaging (MRI) of the brain and ears (T1, SE) – axial plane: area of linear enhancement in the region of the horizontal segment of the left facial nerve and mastoid portion (arrow).



Discussion

FNS is a rare benign tumor that grows from Schwann cells of the facial nerve and is usually slow-growing. It may occur along the entire nerve, from the brainstem to the parotid gland, and the differential diagnoses include other causes of PFP, namely facial nerve hemangioma, vestibular nerve schwannoma, complicated acute otitis media, cholesteatomatous chronic otitis media, paragangliomas, cystic adenoid carcinoma, and parotid gland tumors. The clinical manifestations are not pathognomonic and depend on the size and location of the lesion⁵ (Table 1). In the present case, the patient presented with acute, non-progressive PFP associated with conductive hypoacusis and otalgia. In view of this acute presentation and the inflammatory findings on otoscopy, acute otitis media complicated by PFP was initially suspected rather than a neof ormation, which explains the emergency surgery and absence of preoperative MRI. Imaging is essential in the evaluation of the lesion's characteristics and location. MRI with gadolinium is the most sensitive diagnostic exam and should be complemented by CT, which allows a better assessment of bone involvement (erosion of the facial canal)⁶. Findings that are

compatible with FNS include enlargement of the facial canal in CT and a lesion with hyperintensity in T2 MRI⁶. The combination of clinical manifestations with the imaging findings increases the degree of suspicion. In this case, only ear CT was performed in the ED, which limited the investigation of the clinical manifestations. The treatment options for FNS include surgery, radiotherapy, or clinical and imaging follow-up⁷, although this remains a controversial topic. Surgical treatment includes decompression of the facial nerve and total or subtotal resection of the lesion. The approach (middle fossa, translabyrinthine, transmastoid, or transparotid) should be selected based on the location and extension of the tumor, hearing level, and surgeon's experience⁸ (Table 2). Total resection of the lesion most often involves compromising the function of the facial nerve, and reconstructing the latter is recommended. Several techniques for facial nerve reconstruction can be used: end-to-end anastomosis, nerve graft, and anastomosis between the hypoglossal nerve and facial nerve⁹. The interposition of an autologous nerve graft is the most frequently used technique, with the interposition of sensitive nerves such as the great auricular

Table 1

Location of the FNS and clinical manifestations. Adapted from Cruz et al.⁵

Location	Clinical Manifestations
Cerebellopontine angle and internal auditory canal	Sensorineural hypoacusis and tinnitus
Labyrinthine segment	Progressive PFP and sensorineural hypoacusis
Tympanic segment	Progressive PFP, aural fullness, and conductive hypoacusis
Mastoid segment	Progressive PFP and conductive hypoacusis
Peripheral (after the stylomastoid foramen)	Parotid mass associated with slow-progressing PFP

FNS, Facial nerve schwannoma; PFR, Peripheral facial paralysis.

Table 2

Preferred surgical approaches based on the clinical features and lesion location. Adapted from McMonagle et al.⁸

Preferred approach	Clinical features and lesion location
Middle fossa	Intracanal lesions and good hearing level
Translabyrinthine	Lesions of the internal auditory canal and hearing loss
Transmastoid	Lesions of the tympanic or mastoid segment of the facial nerve

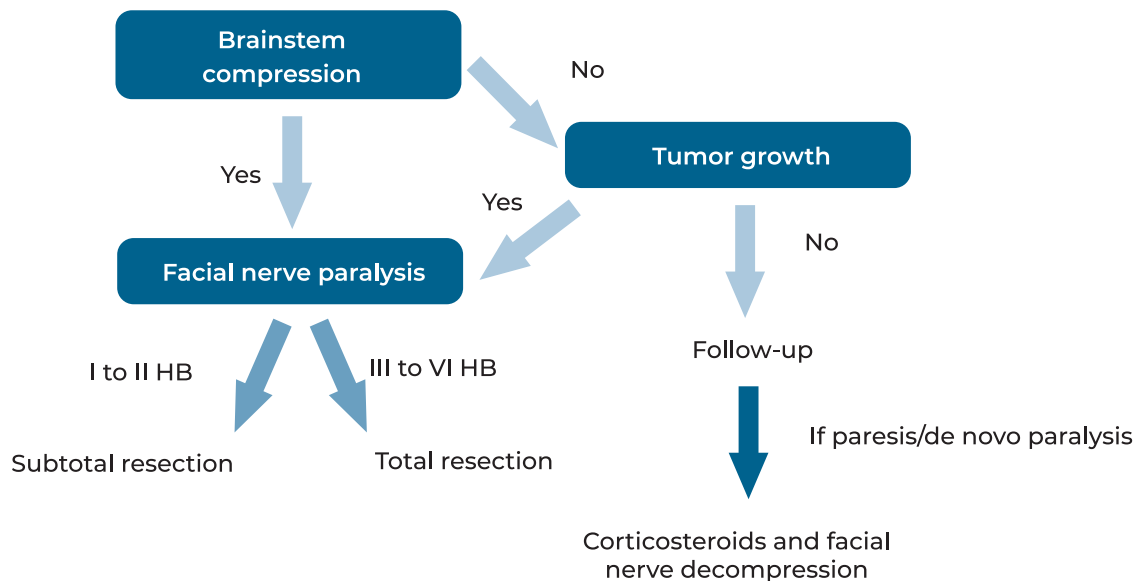
nerve or sural nerve in the leg. Non-resolution of PFP, with eventual worsening of function and hypoacusis and formation of a cerebrospinal fluid (CSF) fistula are potential complications after total resection of an FNS. Subtotal resection is a surgical option that has been increasingly used in the last 20 years⁷. Unlike total resection, it allows preserving the integrity and, consequently, the function of the facial nerve. The available studies are insufficient to assess the long-term outcomes after subtotal resection; however, they show that FNSs stabilize and usually do not regrow. According to a recent study, only one in six FNSs regrows after subtotal resection⁹. Some authors⁷ state that subtotal resection *ab initio* may be considered for patients with good preoperative function (\leq grade III HB). The ideal timing for surgery remains a controversial issue. Some authors⁷ argue in favor of total resection and reconstruction of the facial nerve only when PFP \geq grade IV HB on presentation, and suggest watchful waiting until this grade of facial paralysis is reached. Stereotactic radiosurgery is another therapeutic option for FNS. Most studies on this modality were conducted for cerebellopontine lesions and there is little evidence for its use in intratemporal lesions¹⁰. The results of a meta-analysis¹¹ showed that the rate of tumor control was 93.3% two years after treatment; however, facial nerve function deteriorated in 12.8% of the patients and auditory function worsened in 36.7%. In sum, this therapeutic modality carries significant risks in the treatment of intratemporal lesions and is not considered a first-line treatment. A recent study¹² compared the growth rate of small (< 10 mm) and large (≥ 10 mm) FNSs after a follow-up period of 6.4 years. Tumor growth was observed in 72.7% of the patients with "large lesions" and in only 10% of the patients with "small lesions". Thus, initial watchful waiting in small FNSs (< 10 mm) and FNSs without PFP appears to be a reasonable approach. Monitoring the rate of tumor growth by regular observation and MRI evaluation is recommended. However, in patients with

FNS ≥ 10 mm, the authors suggest that watchful waiting should be reconsidered, even if the facial nerve is functional. Other authors recommend watchful waiting initially until PFP \geq IV HB, regardless of the tumor size, considering that it is a benign lesion which is usually slow-growing and often without a significant PFP grade. The therapeutic modalities have evolved over time and because this is a rare tumor, guidelines on the best treatment options have not been defined; therefore, treatment remains controversial. A recent systematic review⁷ has proposed a treatment algorithm that simplifies the therapeutic approach in patients with intratemporal FNS (Fig. 7). The strategies are first divided according to the presence/absence of brainstem compression:

- If there is brainstem compression or if the tumor exhibits continuous growth (annual assessment by MRI), surgical treatment is indicated with: 1) subtotal resection, if the PFP grade is I-II HB; 2) total resection, if the PFP grade is III-VI.
- If there is no brainstem compression or tumor growth, monitoring is recommended. If acute facial paralysis occurs during follow-up in these patients, decompression of the facial nerve should be performed, along with the administration of corticosteroids. In the present case, the patient was initially presumed to have acute otitis media complicated by PFP, based on the clinical history, objective examination, and findings on emergency CT. It was only after subtotal resection of the granulation tissue surrounding the horizontal and mastoid segment of the facial nerve was performed that the final diagnosis of FNS was made. Because there was a postoperative clinical improvement, both in the PFP grade and auditory thresholds, and the remaining lesion was small, it was decided to undertake watchful waiting, with regular clinical and imaging (MRI) evaluation. Stereotactic radiosurgery was dismissed because it is associated with a significant risk of cochlear damage and worsening of facial nerve function in intratemporal lesions.

Figure 7

Algorithm of the therapeutic approach in patients with intratemporal facial nerve schwannoma (FNS). Adapted from Kitama et al.⁷



Conclusion

Intratemporal FNS is a rare lesion that usually presents with facial paresis and hearing loss. A high index of suspicion is important for early diagnosis and treatment, which should be based on the clinical manifestations and imaging findings. The treatment of intratemporal lesions mainly consists of surgery or watchful waiting because stereotactic radiosurgery is associated with a significant risk of facial and cochlear damage.

Conflicts of Interest

The authors declare that there is no conflict of interests regarding the publication of this paper.

Data Confidentiality

The authors declare having followed the protocols in use at their working center regarding patients' data publication.

Protection of humans and animals

The authors declare that the procedures were followed according to the regulations established by the Clinical Research and Ethics Committee and to the 2013 Helsinki Declaration of the World Medical Association.

Funding Sources

This work did not receive any contribution, funding or scholarship.

Availability of scientific data

There are no datasets available, publicly related to this work.

Bibliographic references

1. Finsterer J. Management of peripheral facial nerve palsy. *Eur Arch Otorhinolaryngol.* 2008 Jul;265(7):743-52. doi: 10.1007/s00405-008-0646-4.
2. Anbarasu A, Chandrasekaran K, Balakrishnan S. Soft tissue attenuation in middle ear on HRCT: Pictorial review. *Indian J Radiol Imaging.* 2012 Oct;22(4):298-304. doi: 10.4103/0971-3026.111483.
3. Lahlou G, Nguyen Y, Russo FY, Ferrary E, Sterkers O, Bernardeschi D. Intratemporal facial nerve schwannoma: clinical presentation and management. *Eur Arch Otorhinolaryngol.* 2016 Nov;273(11):3497-3504. doi: 10.1007/s00405-015-3850-z.
4. Yetiser S. Large intratemporal facial nerve schwannoma without facial palsy: surgical strategy of tumor removal and functional reconstruction. *J Neurol Surg A Cent Eur Neurosurg.* 2018 Nov;79(6):528-532. doi: 10.1055/s-0038-1645868.
5. Cruz S, Trigueiros N, Rodrigues e Rodrigues M. Paralisia facial periférica: caso clínico de schwannoma congénito do nervo facial. *Port J ORL [Internet].* 2011 Set [citado 14 de Janeiro de 2023];49(3):165-8. Disponível em: <https://www.journalsporl.com/index.php/sporl/article/view/178/>.
6. Chung JW, Ahn JH, Kim JH, Nam SY, Kim CJ, Lee KS. Facial nerve schwannomas: different manifestations and

outcomes. *Surg Neurol*. 2004 Sep;62(3):245-52; discussion 452. doi: 10.1016/j.surneu.2003.09.034.

7. Kitama T, Hosoya M, Noguchi M, Nishiyama T, Wakabayashi T, Shimanuki MN. et al. Intratemporal facial nerve schwannomas: a review of 45 Cases in a Single Center. *Diagnostics (Basel)*. 2022 Jul 23;12(8):1789. doi: 10.3390/diagnostics12081789.

8. McMonagle, B.; Al-Sanosi, A.; Croxson, G.R.; A Fagan, P. Facial schwannoma: results of a large case series and review. *J Laryngol Otol*. 2008 Nov;122(11):1139-50. doi: 10.1017/S0022215107000667.

9. Angeli SI, Brackmann DE. Is surgical excision of facial nerve schwannomas always indicated? *Otolaryngol Head Neck Surg*. 1997 Dec;117(6):S144-7. doi: 10.1016/s0194-5998(97)70084-6.

10. Sheehan JP, Kano H, Xu Z, Chiang V, Mathieu D, Chao S. et al. Gamma Knife radiosurgery for facial nerve schwannomas: a multicenter study. *J Neurosurg*. 2015 Aug;123(2):387-94. doi: 10.3171/2014.11.JNS141160.

11. McRackan TR, Wilkinson EP, Brackmann DE, Slattery WH. Stereotactic radiosurgery for facial nerve schwannomas: meta-analysis and clinical review. *Otol Neurotol*. 2015 Mar;36(3):393-8. doi: 10.1097/MAO.0000000000000708.

12. Cho YS, Choi JE, Lim JH, Cho YS. Management of facial nerve schwannoma: when is the timing for surgery. *Eur Arch Otorhinolaryngol*. 2022 Mar;279(3):1243-1249. doi: 10.1007/s00405-021-06765-x.